

Neurology[®]

Table of Contents

Volume 81, Number 4, July 23, 2013

Neurology.org

THE MOST WIDELY READ AND HIGHLY CITED PEER-REVIEWED
NEUROLOGY JOURNAL



IN FOCUS

- 307 Spotlight on the July 23 Issue
- 394 This Week's *Neurology*[®] Podcast




EDITORIALS

- 308 Cognitively stimulating activities to keep dementia at bay
P. Vemuri and E.C. Mormino
- 310 AD and cancer: Epidemiology makes for strange bedfellows
C.M. Roe and M.I. Behrens

IN MEMORIAM

- 312 Jerzy Hildebrand, MD, PhD (1936–2013)
J.-Y. Delattre and C. Vecht

ARTICLES



- 314 Life-span cognitive activity, neuropathologic burden, and cognitive aging
R.S. Wilson, P.A. Boyle, L. Yu, L.L. Barnes, J.A. Schneider, and D.A. Bennett
Editorial, p. 308
- 322 Inverse occurrence of cancer and Alzheimer disease: A population-based incidence study
M. Musicco, F. Adorni, S. Di Santo, F. Prinelli, C. Pettenati, C. Caltagirone, K. Palmer, and A. Russo
Editorial, p. 310
- 329 Differentiating primary progressive aphasias in a brief sample of connected speech
S. Ash, E. Evans, J. O'Shea, J. Powers, A. Boller, D. Weinberg, J. Haley, C. McMillan, D.J. Irwin, K. Rascovsky, and M. Grossman

- 337 Syndromes dominated by apraxia of speech show distinct characteristics from agrammatic PPA
K.A. Josephs, J.R. Duffy, E.A. Strand, M.M. Machulda, M.L. Senjem, V.J. Lowe, C.R. Jack, Jr, and J.L. Whitwell

- 346 Evolution of mild cognitive impairment in Parkinson disease
M. Broeders, R.M.A. de Bie, D.C. Velseboer, J.D. Speelman, D. Muslimovic, and B. Schmand


- 353 Reduced postmovement cortical inhibition in patients with paroxysmal kinesigenic dyskinesia
W.-Y. Hsu, K.-K. Liao, Y.-J. Tseng, S.-Y. Kwan, R.-S. Chen, and Y.-Y. Lin
- 361 Multiparametric MRI study of ALS stratified for the *C9orf72* genotype
P. Bede, A.L.W. Bokde, S. Byrne, M. Elamin, R.L. McLaughlin, K. Kenna, A.J. Fagan, N. Pender, D.G. Bradley, and O. Hardiman
- 370 GFPT1-myasthenia: Clinical, structural, and electrophysiologic heterogeneity
D. Selcen, X.-M. Shen, M. Milone, J. Brengman, K. Ohno, F. Deymeer, R. Finkel, J. Rowin, and A.G. Engel
- 379 Olfactory dysfunction in patients with idiopathic intracranial hypertension
H. Kunte, F. Schmidt, G. Kronenberg, J. Hoffmann, C. Schmidt, L. Harms, and Ö. Goektas
- 383 Electrographic seizures in pediatric ICU patients: Cohort study of risk factors and mortality
N.S. Abend, D.H. Arndt, J.L. Carpenter, K.E. Chapman, K.M. Cornett, W.B. Gallentine, C.C. Giza, J.L. Goldstein, C.D. Hahn, J.T. Lerner, T. Loddenkemper, J.H. Matsumoto, K. McBain, K.B. Nash, E. Payne, S.M. Sánchez, I.S. Fernández, J. Shults, K. Williams, A. Yang, and D.J. Dlugos

GLOBAL PERSPECTIVES

- 392 Neurology and international organizations
F.J. Mateen

CLINICAL/SCIENTIFIC NOTES

- 395 Rasmussen encephalitis treated with natalizumab
S. Bittner, O.J. Simon, K. Göbel, C.G. Bien, S.G. Meuth, and H. Wiendl
 

REFLECTIONS: NEUROLOGY AND THE HUMANITIES

- e20 More than "Just the facts, ma'am"
S.P. Ringel

CONTINUED

Neurology[®]

Table of Contents

continued



NEUROIMAGES

- 398 De novo arteriovenous malformation after brain radiotherapy for medulloblastoma in a child
B. Mathon, T. Blauwblomme, S. Bolle, C. Dufour, O. Nagarra, F. Brunelle, and S. Puget

RESIDENT & FELLOW SECTION

- 400 Clinical Reasoning: A 39-year-old woman with progressive proximal weakness
C. Quinn and C. Karam
- e23 Teaching NeuroImages: Spontaneous thalamic hemorrhage causing convergence excess
Y.-C. Tai, S.-C. Tang, and J.-S. Jeng

- e25 Teaching NeuroImages: Perfusion imaging of cerebral hyperperfusion syndrome following revascularization
V.B. Kalra, B. Rao, and A. Malhotra

WRITECLICK: EDITOR'S CHOICE

- 403 Tumefactive multiple sclerosis lesions under fingolimod treatment
M.O. Kinney, G. McDonnell; Author Response: M.P. Wattjes, F. Visser, B.W. van Oosten
- 403 Stroke in sub-Saharan Africa: An urgent call for prevention
L.B. Goldstein

DEPARTMENT

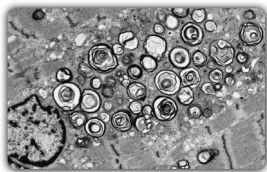
- C3 In the Next Issue of *Neurology*[®]

Podcast at www.neurology.org CME Video Patient Page LOE classification LOE recommendation



Find us on Facebook

tinyurl.com/neurologyfan twitter.com/GreenJournal



Cover image: Electron microscopy finds muscle fiber pathology in patient with GFPT1-related limb-girdle myasthenia, showing a large accumulation of dilated and degenerating vesicular profiles near a nucleus. See page 370.

Look for **Publish Ahead of Print** articles and editorials under the Ahead of Print tab at Neurology.org



Neurology[®] Online CME Program

Earn CME while reading *Neurology*. This program is available only to online *Neurology* subscribers. Simply read the articles marked CME, go to www.neurology.org, and click on CME. This will provide all of the information necessary to get started. The American Academy of Neurology (AAN) is accredited by the Accreditation Council for Continuing Medical Education (ACCME) to sponsor continuing medical education for physicians. *Neurology* is planned and produced in accordance with the ACCME Essentials. For more information, contact AAN Member Services at 800-879-1960.

Neurology[®]

81 (4)

Neurology 2013;81:e25-404

This information is current as of January 1, 2013

Updated Information & Services

including high resolution figures, can be found at:
<http://n.neurology.org/content/81/4.full>

Permissions & Licensing

Information about reproducing this article in parts (figures, tables) or in its entirety can be found online at:
http://www.neurology.org/about/about_the_journal#permissions

Reprints

Information about ordering reprints can be found online:
<http://n.neurology.org/subscribers/advertise>

Neurology® is the official journal of the American Academy of Neurology. Published continuously since 1951, it is now a weekly with 48 issues per year. Copyright . All rights reserved. Print ISSN: 0028-3878. Online ISSN: 1526-632X.

