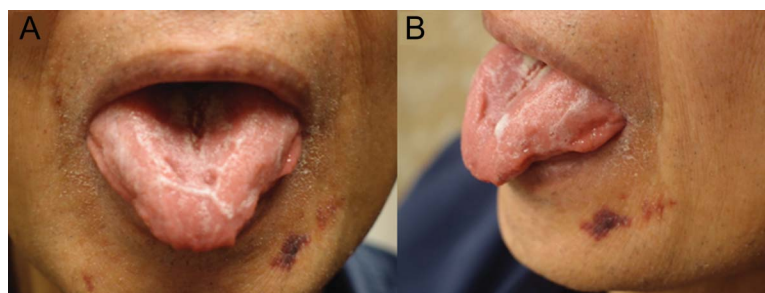


# Teaching *NeuroImages*: Dyspnea as a presenting manifestation of amyloid myopathy

Partha S. Ghosh, MD  
Greg M. Thaera, MD  
Jennifer A. Tracy, MD

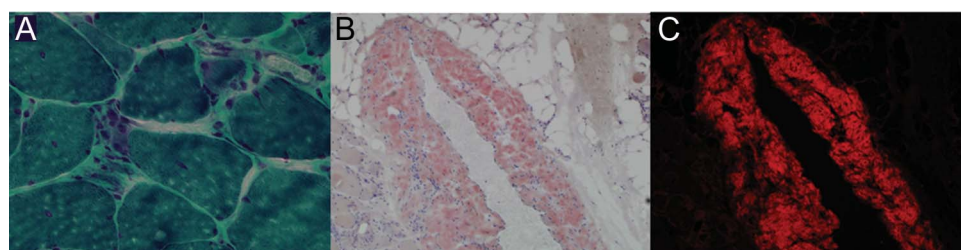
Correspondence to  
Dr. Ghosh:  
ghosh.partha@mayo.edu

**Figure 1** Face photograph showing macroglossia



(A) Front view and (B) side view.

**Figure 2** Frozen sections of the deltoid muscle



(A) Trichrome stain shows a necrotic muscle fiber. (B) Congo red stain shows extensive amyloid deposition in a perimysial blood vessel wall that is intensely red when viewed under rhodamine optics (C).

A 69-year-old man had dyspnea followed by slowly progressive proximal leg weakness over 2 years. He had macroglossia (figure 1). Creatine kinase was 1,378 U/L. A deltoid biopsy revealed myopathy, denervation atrophy, and congophilic deposits around perimysial vessels, indicating amyloid (figure 2). Further workup revealed serum monoclonal lambda protein, bone marrow amyloid, and cardiomyopathy. Amyloid myopathy, an underrecognized entity, predominantly presents with progressive proximal weakness in primary amyloidosis.<sup>1</sup> Dyspnea results from cardiomyopathy or respiratory muscle weakness (our patient had both). Macroglossia due to amyloid deposition is a helpful clinical clue. The patient is on chemotherapy with cyclophosphamide, dexamethasone, and bortezomib, which improves prognosis in amyloidosis.<sup>2</sup>

## AUTHOR CONTRIBUTION

Partha S. Ghosh: drafting/revising the manuscript, study concept or design, analysis or interpretation of data, accepts responsibility for

conduct of research and will give final approval. Greg M. Thaera: analysis or interpretation of data, accepts responsibility for conduct of research and will give final approval, acquisition of data. Jennifer A. Tracy: drafting/revising the manuscript, accepts responsibility for conduct of research and will give final approval, acquisition of data.

## STUDY FUNDING

No targeted funding reported.

## DISCLOSURE

The authors report no disclosures relevant to the manuscript. Go to [Neurology.org](http://Neurology.org) for full disclosures.

## REFERENCES

- Chapin JE, Kornfeld M, Harris A. Amyloid myopathy: characteristic features of a still underdiagnosed disease. *Muscle Nerve* 2005;31:266–272.
- Venner CP, Lane T, Foard D, et al. Cyclophosphamide, bortezomib, and dexamethasone therapy in AL amyloidosis is associated with high clonal response rates and prolonged progression-free survival. *Blood* 2012;119:4387–4390.

# Neurology®

## Teaching *NeuroImages*: Dyspnea as a presenting manifestation of amyloid myopathy

Partha S. Ghosh, Greg M. Thaera and Jennifer A. Tracy

*Neurology* 2013;81:e184

DOI 10.1212/01.wnl.0000437300.51312.9e

**This information is current as of December 9, 2013**

<b>Updated Information &amp; Services</b>	including high resolution figures, can be found at: <a href="http://n.neurology.org/content/81/24/e184.full">http://n.neurology.org/content/81/24/e184.full</a>
<b>Supplementary Material</b>	Supplementary material can be found at: <a href="http://n.neurology.org/content/suppl/2013/12/07/81.24.e184.DC1">http://n.neurology.org/content/suppl/2013/12/07/81.24.e184.DC1</a>
<b>References</b>	This article cites 2 articles, 1 of which you can access for free at: <a href="http://n.neurology.org/content/81/24/e184.full#ref-list-1">http://n.neurology.org/content/81/24/e184.full#ref-list-1</a>
<b>Errata</b>	An erratum has been published regarding this article. Please see <a href="#">next page</a> or: <a href="/content/82/2/189.2.full.pdf">/content/82/2/189.2.full.pdf</a>
<b>Permissions &amp; Licensing</b>	Information about reproducing this article in parts (figures, tables) or in its entirety can be found online at: <a href="http://www.neurology.org/about/about_the_journal#permissions">http://www.neurology.org/about/about_the_journal#permissions</a>
<b>Reprints</b>	Information about ordering reprints can be found online: <a href="http://n.neurology.org/subscribers/advertise">http://n.neurology.org/subscribers/advertise</a>

*Neurology*® is the official journal of the American Academy of Neurology. Published continuously since 1951, it is now a weekly with 48 issues per year. Copyright © 2013 American Academy of Neurology. All rights reserved. Print ISSN: 0028-3878. Online ISSN: 1526-632X.



8. Saidha S, Sotirchos ES, Ibrahim MA, et al. Microcystic macular oedema, thickness of the inner nuclear layer of the retina, and disease characteristics in multiple sclerosis: a retrospective study. *Lancet Neurol* 2012;11:963–972.

### OLFACTORY DYSFUNCTION IN PATIENTS WITH IDIOPATHIC INTRACRANIAL HYPERTENSION

**Kah Fang Khoo, Bayan Lepas, Malaysia:** This interesting pilot study<sup>1</sup> provides new evidence that patients with idiopathic intracranial hypertension (IIH) may have olfactory dysfunction. This feature is added to more conventional symptoms like headache, nausea, vomiting, and double vision. This is helpful as the Sniffin' Sticks procedure is less invasive than lumbar puncture and less expensive than MRI. Schmidt et al.<sup>2</sup> demonstrated reduction of olfactory bulb volume using MRI. A future study should include reduction of olfactory function as one of the minor criteria for diagnosing IIH and rule out space-occupying lesions and high intracranial pressure.

**Author Response: Hagen Kunte, Felix Schmidt, Jan Hoffmann, Lutz Harms, Golo Kronenberg, Berlin:** We appreciate the suggestion that an assessment of olfactory function by the extended Sniffin' Sticks procedure may be helpful in the diagnosis and

follow-up of IIH. The prevalence of absolute hyposmia in patients with a recent first diagnosis of IIH or patients with a clinically significant worsening of IIH within the last 3 months reached 80% in our sample.<sup>1</sup> We agree that the presence of olfactory dysfunction should be considered as one of the minor criteria for diagnosing IIH. However, other potential causes of reduced olfactory function must first be ruled out. In contrast, olfactory testing is less appropriate as a follow-up measure in patients with diagnosed IIH because olfactory function typically trails changes in intracranial pressure (ICP) by several weeks. Emerging evidence suggests that 3D spectral-domain optical coherence tomography of the optic nerve head might be used to noninvasively monitor IIH and possibly other disorders with increased ICP.<sup>3</sup>

© 2014 American Academy of Neurology

1. Kunte H, Schmidt F, Kronenberg G, et al. Olfactory dysfunction in patients with idiopathic intracranial hypertension. *Neurology* 2013;81:379–382.
2. Schmidt C, Wiener E, Hoffmann J, et al. Structural olfactory nerve changes in patients suffering from idiopathic intracranial hypertension. *PLoS One* 2012;7:e35221.
3. Kauffhold F, Kadas EM, Schmidt C, et al. Optic nerve head quantification in idiopathic intracranial hypertension by spectral domain OCT. *PLoS One* 2012;7:e36965.

### CORRECTION

#### Teaching NeuroImages: Dyspnea as a presenting manifestation of amyloid myopathy

In regard to the article "Teaching NeuroImages: Dyspnea as a presenting manifestation of amyloid myopathy" by P.S. Ghosh et al. (*Neurology*® 2013;81:e184), there is an error in the cover image text found at the end of the Table of Contents. It should have read: "Trichrome stain of a deltoid muscle showing a necrotic muscle fiber in a patient with amyloid myopathy." The authors regret the error.