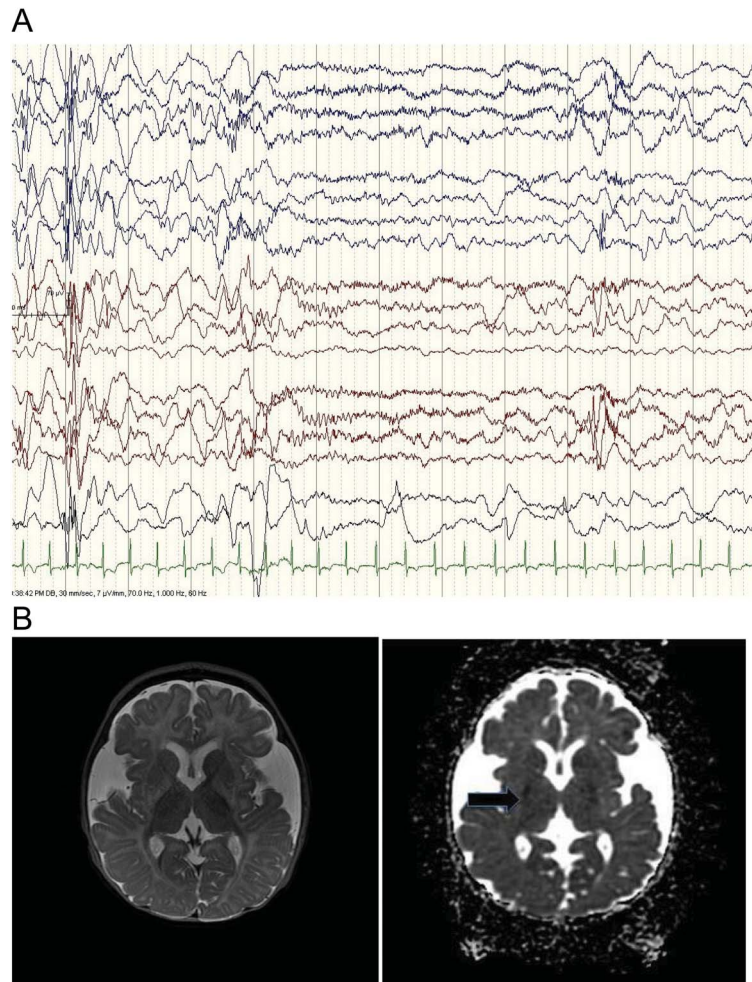


Teaching *NeuroImages*: Infant with glutaric aciduria type 1 presenting with infantile spasms and hypersarhythmia

Nichole Young-Lin, BA
Sarah Shalev, MD
Orit A. Glenn, MD
Marisa Gardner, MD
Chung Lee, MD
Anthony Wynshaw-Boris,
MD, PhD
Amy A. Gelfand, MD

Correspondence to
Dr. Gelfand:
GelfandA@neuropeds.ucsf.edu

Figure EEG and brain MRI findings



(A) Hypersarhythmia on EEG. EEG at presentation showed hypersarhythmia: high voltages, disorganization, and frequent multifocal and generalized spikes. (B) Acute basal ganglia injury. T2-weighted image demonstrates widened opercula and increased T2 signal in globi pallidi and dorsal putamina. Apparent diffusion coefficient image shows subtle reduced diffusion in the globus pallidi.

A 7-month-old boy with glutaric aciduria type 1 (GA1) presented with 1 week of clustered flexor spasms. Examination revealed mild axial hypotonia without encephalopathy. Video-EEG monitoring revealed hypersarhythmia and infantile spasms (figure, A). MRI showed acute basal ganglia injury (figure, B). After 3 weeks of prednisolone treatment,

5-month follow-up showed continued resolution of hypersarhythmia and spasms.

GA1 is an autosomal recessive condition due to deficiency of the enzyme necessary for degradation of lysine, tryptophan, and hydroxylysine. Infantile spasms have only been reported once before in GA1.¹ New-onset spasms may be associated with

Download teaching slides:
www.neurology.org

From the University of California, San Francisco School of Medicine (N.Y.-L.); Division of Epilepsy (S.S.) and Division of Child Neurology (M.G., A.A.G.), Department of Neurology; Division of Pediatric Neuroradiology (O.A.G.), Department of Radiology; and Division of Medical Genetics (C.L., A.W.-B.), Department of Pediatrics (A.A.G.), University of California, San Francisco.

Go to Neurology.org for full disclosures. Funding information and disclosures deemed relevant by the authors, if any, are provided at the end of the article.

suboptimal metabolic control, even in the absence of encephalopathy.²

AUTHOR CONTRIBUTIONS

Nichole Young-Lin: participated in conceptualization of the manuscript, drafted the manuscript and figure legend, and revised the manuscript for intellectual content. Sarah Shalev: selected appropriate EEG images (i.e., interpretation of data) and revised the manuscript for intellectual content. Orit A. Glenn: selected appropriate brain MRI images (i.e., interpretation of data) and revised the manuscript for intellectual content. Marisa Gardner: participated in analysis of results and revised the manuscript for intellectual content. Chung Lee: revised the manuscript for intellectual content. Anthony Wynshaw-Boris: participated in conceptualization of the manuscript and revised the manuscript for intellectual content. Amy A. Gelfand: participated in conceptualization of the manuscript and revised the manuscript for intellectual content.

STUDY FUNDING

No targeted funding reported.

DISCLOSURE

N. Young-Lin reports no disclosures. S. Shalev reports no disclosures. O. Glenn reports no disclosures. M. Gardner reports no disclosures. C. Lee reports no disclosures. A. Wynshaw-Boris received grants from NIH/NINDS and NIH/NIGMS. A. Gelfand received research grant support from NIH/NINDS (K12NS001692) and the UCSF Clinical and Translational Science Institute; she has received personal compensation for legal consulting as well as honoraria from Journal Watch Neurology. Go to Neurology.org for full disclosures.

REFERENCES

1. Singh P, Goraya JS, Ahluwalia A, Saggar K. Teaching NeuroImages: glutaric aciduria type 1 (glutaryl-CoA dehydrogenase deficiency). *Neurology* 2011;77:e6.
2. Kolker S, Christensen E, Leonard JV, et al. Diagnosis and management of glutaric aciduria type I—revised recommendations. *J Inher Metab Dis* 2011;34:677–694.

Neurology®

Teaching *NeuroImages*: Infant with glutaric aciduria type 1 presenting with infantile spasms and hypsarrhythmia

Nichole Young-Lin, Sarah Shalev, Orit A. Glenn, et al.

Neurology 2013;81:e182-e183

DOI 10.1212/01.wnl.0000437291.75075.53

This information is current as of December 9, 2013

Updated Information & Services	including high resolution figures, can be found at: http://n.neurology.org/content/81/24/e182.full
Supplementary Material	Supplementary material can be found at: http://n.neurology.org/content/suppl/2013/12/07/81.24.e182.DC1
References	This article cites 2 articles, 1 of which you can access for free at: http://n.neurology.org/content/81/24/e182.full#ref-list-1
Subspecialty Collections	This article, along with others on similar topics, appears in the following collection(s): All Pediatric http://n.neurology.org/cgi/collection/all_pediatric Metabolic disease (inherited) http://n.neurology.org/cgi/collection/metabolic_disease_inherited
Permissions & Licensing	Information about reproducing this article in parts (figures, tables) or in its entirety can be found online at: http://www.neurology.org/about/about_the_journal#permissions
Reprints	Information about ordering reprints can be found online: http://n.neurology.org/subscribers/advertise

Neurology® is the official journal of the American Academy of Neurology. Published continuously since 1951, it is now a weekly with 48 issues per year. Copyright © 2013 American Academy of Neurology. All rights reserved. Print ISSN: 0028-3878. Online ISSN: 1526-632X.

