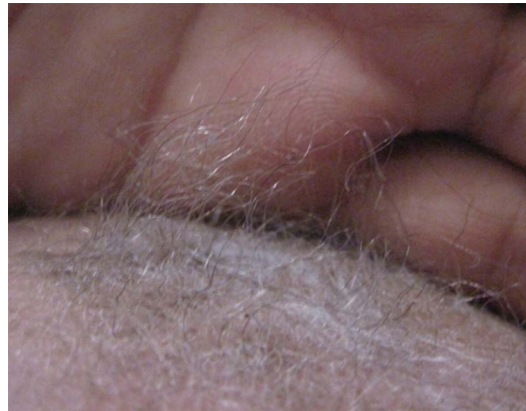

# Teaching NeuroImages: Menkes kinky hair syndrome

Roopa Seshadri, MD,  
DM  
P.S. Bindu, DM  
A.K. Gupta, MD

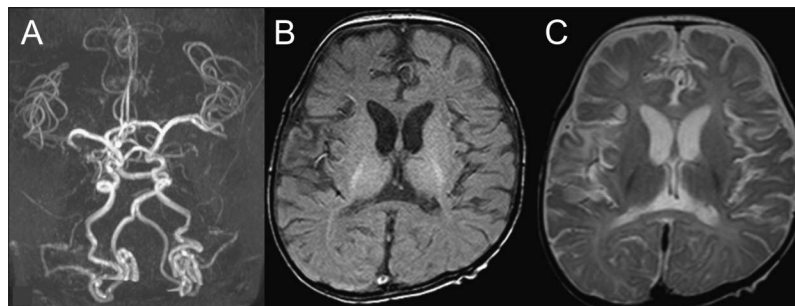
Correspondence to  
Dr. Seshadri:  
drroopastjohns@gmail.com

**Figure 1** Characteristics of scalp hair in Menkes disease



Hair is sparse, short, thin, fragile, and light-colored, and has a steel-wool appearance.

**Figure 2** Imaging



(A) Magnetic resonance angiography reveals highly tortuous arteries of the brain. (B) T1 and (C) T2 MRI sequences demonstrate generalized neuroatrophy and delayed myelination.

Six-month-old twins, born to a consanguineous couple, presented with hypotonia, hypothermia, seizures, and developmental delay. The babies were fair complexioned; scalp hairs were sparse, light-colored, and fragile (figure 1), with regularly spaced twists (pili-torti) and nodes (trichorrhexis-nodosa). MRI brain revealed generalized atrophy with tortuous arteries (figure 2). Low plasma copper and ceruloplasmin levels confirmed Menkes syndrome.

Menkes syndrome is an infantile X-linked recessive neurodegenerative disorder caused by missense

mutations in the *ATP7A* gene (copper transport gene on chromosome Xq21.1), which causes copper deficiency. Reduced activity of copper-dependent enzymes leads to abnormalities in connective tissue, blood vessels, and hair.<sup>1</sup> X-rays might reveal widening of metaphysis with spurring.<sup>1,2</sup> Early treatment with parenteral copper histidine might stop the progressive neurodegeneration.<sup>1,2</sup>

#### AUTHOR CONTRIBUTIONS

Dr. Seshadri studied the case, collected the information, and compiled the manuscript. Drs. Bindu and Gupta reviewed the manuscript.

From the Departments of Neuroimaging and Interventional Radiology (R.S., A.K.G.) and Neurology (P.S.B.), National Institute of Mental Health & Neuro Sciences, Bangalore, India.

Go to [Neurology.org](http://Neurology.org) for full disclosures. Funding information and disclosures deemed relevant by the authors, if any, are provided at the end of the article.

## STUDY FUNDING

No targeted funding reported.

## DISCLOSURE

The authors report no disclosures relevant to the manuscript. Go to [Neurology.org](http://Neurology.org) for full disclosures.

## REFERENCES

1. Kim YH, Lee R, Yoo HW, et al. Identification of a novel mutation in the *ATP7A* gene in a Korean patient with Menkes disease. *J Korean Med Sci* 2011;26:951–953.
2. Inamadar AC, Aparna P. Neurodegenerative disorders with hair abnormalities: an emergency room consultation for dermatologists. *Int J Trichology* 2009;1:30–32.

# Neurology®

## Teaching *NeuroImages*: Menkes kinky hair syndrome

Roopa Seshadri, P.S. Bindu and A.K. Gupta

*Neurology* 2013;81:e12-e13

DOI 10.1212/WNL.0b013e31829a334c

**This information is current as of July 8, 2013**

<b>Updated Information &amp; Services</b>	including high resolution figures, can be found at: <a href="http://n.neurology.org/content/81/2/e12.full">http://n.neurology.org/content/81/2/e12.full</a>
<b>References</b>	This article cites 2 articles, 0 of which you can access for free at: <a href="http://n.neurology.org/content/81/2/e12.full#ref-list-1">http://n.neurology.org/content/81/2/e12.full#ref-list-1</a>
<b>Permissions &amp; Licensing</b>	Information about reproducing this article in parts (figures, tables) or in its entirety can be found online at: <a href="http://www.neurology.org/about/about_the_journal#permissions">http://www.neurology.org/about/about_the_journal#permissions</a>
<b>Reprints</b>	Information about ordering reprints can be found online: <a href="http://n.neurology.org/subscribers/advertise">http://n.neurology.org/subscribers/advertise</a>

*Neurology*® is the official journal of the American Academy of Neurology. Published continuously since 1951, it is now a weekly with 48 issues per year. Copyright © 2013 American Academy of Neurology. All rights reserved. Print ISSN: 0028-3878. Online ISSN: 1526-632X.

