



Clinical Reasoning: A girl presenting with stiffness episodes during sleep, café-au-lait spots, and flecked retina

Romina Moavero, MD
Raffaella Cusmai, MD
Maria Cristina Roberti,
PhD
Federico Vigevano, MD
Paolo Curatolo, MD

Correspondence to
Dr. Moavero:
rominamoavero@hotmail.com

SECTION 1

A 4-year-old girl who had been born of normal pregnancy and delivery and had an unremarkable family or personal history was referred to a neuropsychiatric department because of the appearance of peculiar nocturnal episodes. Parents described that their child abruptly became stiff during sleep. These episodes usually ranged from 20 to 40 seconds, and after that the child continued to sleep. Initially she presented 1 episode per week, but there was a progressive increase in frequency up to 3 to 4 times per night. The child never presented similar episodes while awake. Her examination revealed some

café-au-lait spots, congenital microcephaly (3rd centile) and low stature for the age (10th centile). She did not present any neurologic deficit, but she failed to develop an age-appropriate speech, with a delay in the main language milestones.

Questions for consideration:

1. What is the differential diagnosis for children presenting with nocturnal episodes apparently characterized only by stiffness, without awakening and with no apparent neurologic sign?
2. What are the initial steps to evaluate this child?

[GO TO SECTION 2](#)

From the Pediatric Neurology Unit (R.M., P.C.), Neuroscience Department, Tor Vergata University Hospital, Rome; and Division of Neurology (R.C., F.V.) and Cytogenetics and Molecular Genetics Unit (M.C.R.), “Bambino Gesù” Children’s Hospital, IRCCS, Rome, Italy.

Go to Neurology.org for full disclosures. Funding information and disclosures deemed relevant by the authors, if any, are provided at the end of the article.

SECTION 2

The most important differential diagnosis in a child presenting with stiffness episodes only during sleep is between a sleep disorder and epileptic seizures. At first, the child neurologist who visited the girl diagnosed a sleep disturbance similar to “pavor nocturnus” without prescribing any other assessment or therapies. She continued to present 4 to 5 episodes per night, and at the age of 6 years she was referred to us. Parents were again asked to describe their child’s episodes, and they confirmed that the girl abruptly became stiff but they added that during these episodes she tended to present asymmetric and peculiar postures. We therefore thought that the clinical appearance was compatible with epileptic seizures, and we immediately performed an awake and

sleep video-EEG. They showed a good awake background activity (alpha rhythm in the posterior regions) and a good sleep organization with symmetric sleep spindles and K complexes. However, sharp and slow waves in the right centrotemporal regions were recorded both during awake and sleep EEG with no evidence of any clinical events.

Questions for consideration:

1. What is the differential diagnosis of a child presenting with centrotemporal spikes and waves and with nocturnal seizures?
2. What should a child neurologist do in case of detection of centrotemporal spike and wave EEG abnormalities in a child with nocturnal seizures?

[GO TO SECTION 3](#)

SECTION 3

Centrotemporal epileptiform EEG abnormalities in a child presenting with nocturnal seizures should lead the child neurologist to think about the possibility of a benign epilepsy with centrotemporal spikes (BECTS). However, in our case, epileptiform abnormalities were rather different from the ones usually observed in BECTS, that is, generally characterized by spikes, rarely followed by slow waves, which tend to significantly increase during sleep. Furthermore, nocturnal seizures in BECTS are usually characterized by motor focal seizures with secondary generalization, sometimes with postictal paralysis and/or aphasia. Another possible differential diagnosis is Landau-Kleffner syndrome (LKS). This is a form of acquired childhood aphasia with mainly bitemporal paroxysmal EEG abnormalities, which occurs in previously normal children with an age-appropriate speech. To discriminate between these 2 situations, a dipole orientation analysis on the EEG could be of help, because the orientation of the dipole vertically to the planum temporale (intra-perisylvian region) appears to be associated with the findings in LKS,

whereas BECTS is always associated with a tangential dipole.

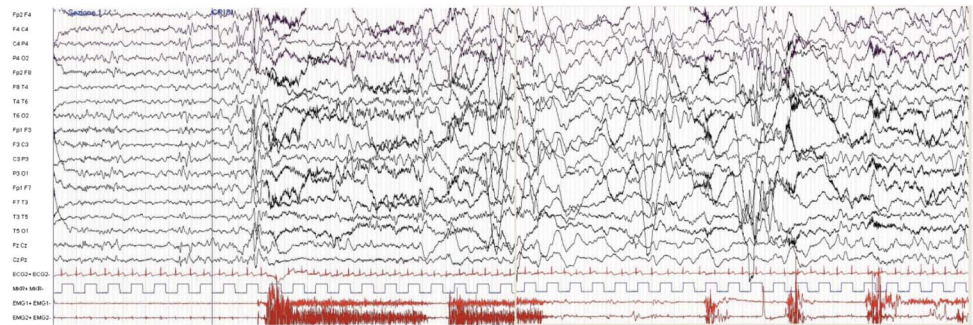
However, in this case, we were faced with a girl with a preexisting language delay and presenting asymmetric tonic posturing and focal epileptiform abnormalities, not fitting the diagnosis of BECTS or LKS. To exclude a structural lesion that could cause seizures, we performed an MRI that was completely normal. A physical and neurologic examination confirmed the lack of any neurologic sign or deficit, but revealed the presence of 15 café-au-lait spots (mostly on arms and trunk, ranging from 0.5 to 2 cm in diameter). She presented microcephaly (3rd percentile) and low stature for the age (<5th percentile); however, she did not present any other peculiar dysmorphisms.

Questions for consideration:

1. Once excluding BECTS and symptomatic focal epilepsy, is it necessary to start a treatment?
2. What kind of antiepileptic drug is most suitable in this case?
3. Might it be valuable to monitor the neurocognitive aspects of the girl?

GO TO SECTION 4

Figure 1 Ictal EEG with polygraphic deltoids registration showing a generalized tonic seizure during sleep



SECTION 4

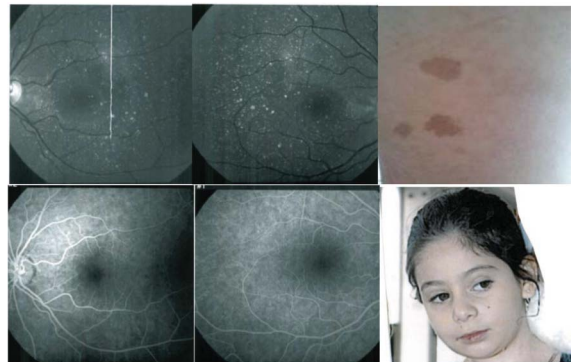
Even though seizures presented only during night sleep, they presented with a very high frequency. Therefore, we discussed with the parents the possibility of introducing an antiepileptic treatment. Because of the focal EEG and clinical features, we decided to begin with carbamazepine, titrating it up to the maximum therapeutic dosage, without any reduction in the seizure frequency and severity. Therefore, we decided to add topiramate, without any improvement in seizure frequency. The girl was now 8 years old and neurologic and objective examinations suggested slowness in cognitive acquisitions. Because sleep epileptiform abnormalities may disturb learning processings, a close monitoring of neurocognitive function of the child was performed. At first she only presented a language delay, but when she entered primary school, she began presenting learning difficulties, and a cognitive evaluation detected a borderline cognitive level. Topiramate was discontinued and replaced at first with lamotrigine, but when this drug showed no efficacy, we tried levetiracetam without any significant modification of the electroclinical situation.

At the age of 8 years, clinical and EEG findings were suggestive of an epileptic encephalopathy (figures 1 and 2). The girl continued to present multiple daily seizures with a progressive worsening of the neurocognitive aspects. Cognitive level deteriorated up to a mild mental retardation, with a subsequent severe learning deficit. Furthermore, she also presented with ataxia. During an ophthalmologic examination, a flecked retina with subretinal drusen-like deposits was detected. To better investigate the flecked aspect of her retina, we performed an electroretinogram and visual evoked potentials, which were normal.

Questions for consideration:

1. What can be the next step in the treatment of this child?
2. Is there any other diagnostic assessment to perform to try to understand the etiology of this severe form of focal epilepsy?
3. Could the presence of skin and retinal abnormalities suggest any underlying etiology?

Figure 2 Clinical features included flecked aspect of the retina and 3 café-au-lait spots on the trunk; at lower right is a photograph of the girl at age 5 years



GO TO SECTION 5

SECTION 5

As soon as the epileptic encephalopathy was detected, possible therapeutic strategies including pharmacologic (i.e., adrenocorticotrophic hormone, hydrocortisone) and nonpharmacologic options (vagus nerve stimulation, ketogenic diet) were considered. We decided to administer adrenocorticotrophic hormone as a first choice and we obtained good clinical results: ataxia disappeared, the EEG significantly ameliorated, and the girl remained seizure-free for about 2 months. Subsequently, seizures appeared again, at first with a weekly and later with a daily frequency. Because of the coexistence of intractable epilepsy, mental retardation, and skin abnormalities, we performed a high-resolution karyotype, which showed the presence of a mosaic ring 17 chromosome in 65% of the analyzed cells; a subsequent array comparative genomic hybridization appeared to be normal.

DISCUSSION Ring chromosomes usually derive from the deletion and subsequent fusion of the telomeric chromosomal regions; only rings 14, 17, and 20 seem to be associated with a high risk of developing epileptic seizures with different phenotypes.¹ Ring chromosome 17 is a rare genetic abnormality described, to date, in 17 patients.² Seizures, mental retardation, skin manifestations, and reduced growth are very common in affected subjects. However, the clinical phenotype is highly variable, and this can be in relation to the deletion size.³ Patients presenting a deletion involving 17p13.3 have a Miller-Dieker syndrome with lissencephaly. The presence of skin abnormalities such as the café-au-lait spots in ring chromosome syndromes may reflect mosaicism due to chromosome instability.³ Our patient is the sixth patient who presented a flecked retina in association with ring 17 chromosome,⁴ suggesting that loci on chromosome 17 may be involved in the regulation of retinal pigment epithelial or photoreceptor function. Flecks might be attributable to abnormal retinal pigmentation, similar to the café-au-lait spots seen on the skin.^{3,4}

The epileptic phenotype associated with ring 17 chromosome does not show peculiar clinical and EEG findings, which can be of help in other genetic causes of drug-resistant seizures, such as ring 20 chromosome. There is some evidence of an overlapping phenotype between these 2 syndromes, but this is an exception rather than the rule.¹ Because available literature data on this genetic abnormality only report brief descriptions

of the epileptic phenotype of affected subjects, it is difficult to find common aspects that may be considered highly suggestive for this disease. Nonetheless, the association of flecked retina, café-au-lait spots, cognitive impairment, and epilepsy should raise the clinical suspicion of ring 17 chromosome and thus lead to performing a high-resolution karyotype.^{5,6} The detection of a ring chromosome needs a subsequent array comparative genomic hybridization confirmation in order to exclude a concomitant critical deletion in the derivative chromosome.

An underlying genetic cause for epilepsy should always be hypothesized in all the cases of intractable epilepsy with normal neuroimaging, mainly when associated with mental retardation, skin abnormalities, dysmorphic features, and, as suggested by the reports of ring 17 chromosome, retinal abnormalities, microcephaly, and low stature, alone or in combination.

AUTHOR CONTRIBUTIONS

Dr. Moavero and Dr. Cusmai firstly projected to write this kind of report. Dr. Moavero wrote the first draft of the manuscript. Dr. Roberti and Dr. Moavero reviewed all of the literature concerning ring 17 chromosome and of genetics epilepsies. Dr. Roberti undertook the genetic aspects of this manuscript. Dr. Vigeveno and Dr. Curatolo revised the manuscript step by step and approved its final version.

STUDY FUNDING

No targeted funding reported.

DISCLOSURE

The authors report no disclosures relevant to the manuscript. Go to Neurology.org for full disclosures.

REFERENCES

1. Ricard-Mousnier B, N'Guyen S, Dubas F, Poupard F, Guichet A. Ring chromosome 17 epilepsy may resemble that of ring chromosome 20 syndrome. *Epileptic Disord* 2007;9:327–331.
2. Surace C, Piazzolla S, Sireto P, et al. Mild ring 17 syndrome shares common phenotypic features irrespective of the chromosomal breakpoints location. *Clin Genet* 2009;76:256–262.
3. Shashi V, White JR, Pettenati MJ, Root SK, Bell WL. Ring chromosome 17: phenotype variation by deletion size. *Clin Genet* 2003;64:361–365.
4. Charles SJ, Moore AT, Davison BC, Dyson HM, Willatt L. Flecked retina associated with ring 17 chromosome. *Br J Ophthalmol* 1991;75:125–127.
5. Gass JD, Taney BS. Flecked retina associated with café au lait spots, microcephaly, epilepsy, short stature, and ring 17 chromosome. *Arch Ophthalmol* 1994;112:738–739.
6. Qazi OH, Madahar C, Kanchanapoomi R, Giridharan R, Beller E. Ring chromosome 17 in a mentally retarded boy. *Ann Genet* 1979;22:234–238.

Neurology®

Clinical Reasoning: A girl presenting with stiffness episodes during sleep, café-au-lait spots, and flecked retina

Romina Moavero, Raffaella Cusmai, Maria Cristina Roberti, et al.

Neurology 2013;80:e42-e46

DOI 10.1212/WNL.0b013e31827f1346

This information is current as of January 28, 2013

Updated Information & Services	including high resolution figures, can be found at: http://n.neurology.org/content/80/5/e42.full
References	This article cites 6 articles, 1 of which you can access for free at: http://n.neurology.org/content/80/5/e42.full#ref-list-1
Subspecialty Collections	This article, along with others on similar topics, appears in the following collection(s): All Clinical Neurology http://n.neurology.org/cgi/collection/all_clinical_neurology All Epilepsy/Seizures http://n.neurology.org/cgi/collection/all_epilepsy_seizures All Genetics http://n.neurology.org/cgi/collection/all_genetics EEG http://n.neurology.org/cgi/collection/eeg_
Permissions & Licensing	Information about reproducing this article in parts (figures, tables) or in its entirety can be found online at: http://www.neurology.org/about/about_the_journal#permissions
Reprints	Information about ordering reprints can be found online: http://n.neurology.org/subscribers/advertise

Neurology® is the official journal of the American Academy of Neurology. Published continuously since 1951, it is now a weekly with 48 issues per year. Copyright © 2013 American Academy of Neurology. All rights reserved. Print ISSN: 0028-3878. Online ISSN: 1526-632X.

