

# Teaching Video NeuroImages: Acute Adie syndrome



Benjamin R. Wakerley,  
PhD, MRCP  
Mei Hong Tan, MB,  
ChB, BAO, PhD,  
FRCOphth  
Martin R. Turner,  
PhD, FRCP

Correspondence & reprint  
requests to Dr. Turner:  
martin.turner@ndcn.ox.ac.uk

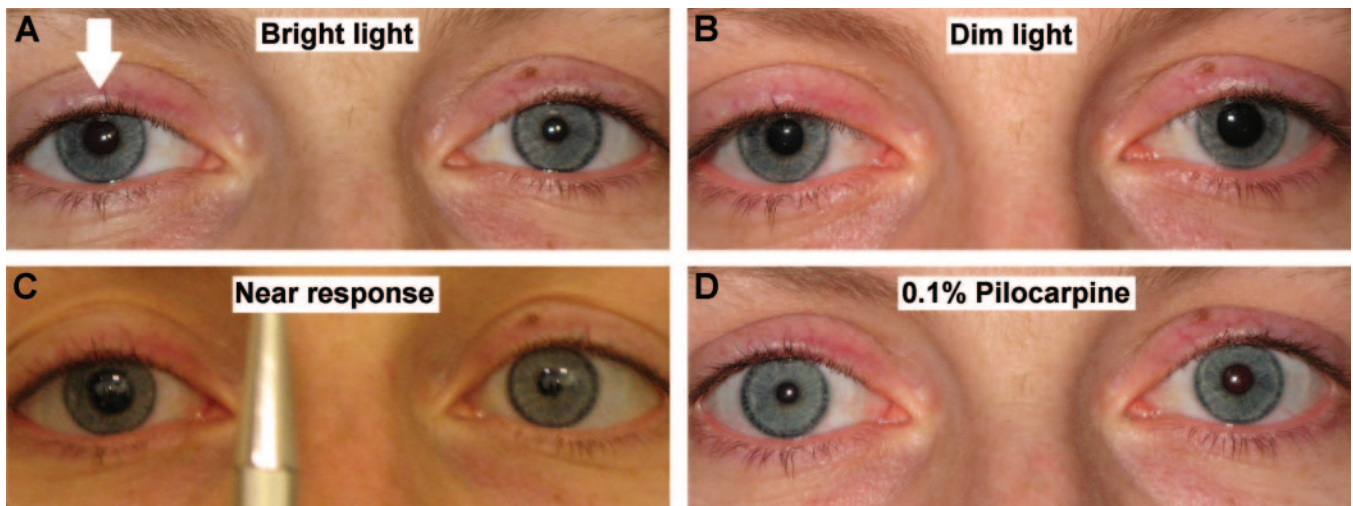
A healthy 30-year-old woman reported acute painless enlargement of the right pupil, associated with mild ipsilateral photophobia and blurring. An enlarged right pupil was observed, constricting poorly to light and with segmental vermiform movements (figure). Generalized deep tendon hyporeflexia was noted. The tonic right pupil constricted 30 minutes after instillation of dilute pilocarpine (0.1%) solution. William John Adie<sup>1</sup> (1886–1935) described this benign condition predominantly in young women, postulated to be secondary to

viral ciliary ganglionitis. Russell<sup>2</sup> noted cases with a poor near as well as light response, which we postulate may be a feature of an acute syndrome.

## REFERENCES

1. Adie WJ. Tonic pupils and absent tendon reflexes: a benign disorder sui generis; its complete and incomplete forms. *Brain* 1932;55:98–113.
2. Russell GFM. The pupillary changes in the Holmes-Adie Syndrome. *J Neurol Neurosurg Psychiatry* 1956;19:289–296.

**Figure** Pupil appearances in Adie syndrome



Parasympathetic denervation of the iris sphincter muscle in Adie syndrome results in an enlarged tonic right pupil reacting poorly to light (A, B). Near response was also impaired (C). It is supersensitive to cholinergic agents (pilocarpine 0.1%) (D). Paralysis of the iris results in characteristic segmental vermiform movements. These are visible superolaterally acutely and inferomedially 6 months later (video on the *Neurology*<sup>®</sup> Web site at [www.neurology.org](http://www.neurology.org)).

Supplemental data at  
[www.neurology.org](http://www.neurology.org)

From the Departments of Neurology (B.R.W.) and Ophthalmology (M.H.T.), Oxford University Nuffield Department of Clinical Neurosciences (M.R.T.), John Radcliffe Hospital, Oxford, UK.

The authors report no disclosures relevant to the manuscript. Go to *Neurology.org* for full disclosures.

# Neurology®

**Teaching Video NeuroImages: Acute Adie syndrome**  
Benjamin R. Wakerley, Mei Hong Tan and Martin R. Turner  
*Neurology* 2012;79:e97  
DOI 10.1212/WNL.0b013e3182698cc5

**This information is current as of September 10, 2012**

<b>Updated Information &amp; Services</b>	including high resolution figures, can be found at: <a href="http://n.neurology.org/content/79/11/e97.full">http://n.neurology.org/content/79/11/e97.full</a>
<b>Supplementary Material</b>	Supplementary material can be found at: <a href="http://n.neurology.org/content/suppl/2012/09/08/79.11.e97.DC1">http://n.neurology.org/content/suppl/2012/09/08/79.11.e97.DC1</a>
<b>References</b>	This article cites 2 articles, 1 of which you can access for free at: <a href="http://n.neurology.org/content/79/11/e97.full#ref-list-1">http://n.neurology.org/content/79/11/e97.full#ref-list-1</a>
<b>Subspecialty Collections</b>	This article, along with others on similar topics, appears in the following collection(s): <b>Clinical neurology examination</b> <a href="http://n.neurology.org/cgi/collection/clinical_neurology_examination">http://n.neurology.org/cgi/collection/clinical_neurology_examination</a> <b>Pupils</b> <a href="http://n.neurology.org/cgi/collection/pupils">http://n.neurology.org/cgi/collection/pupils</a> <b>Viral infections</b> <a href="http://n.neurology.org/cgi/collection/viral_infections">http://n.neurology.org/cgi/collection/viral_infections</a>
<b>Permissions &amp; Licensing</b>	Information about reproducing this article in parts (figures, tables) or in its entirety can be found online at: <a href="http://www.neurology.org/about/about_the_journal#permissions">http://www.neurology.org/about/about_the_journal#permissions</a>
<b>Reprints</b>	Information about ordering reprints can be found online: <a href="http://n.neurology.org/subscribers/advertise">http://n.neurology.org/subscribers/advertise</a>

*Neurology*® is the official journal of the American Academy of Neurology. Published continuously since 1951, it is now a weekly with 48 issues per year. Copyright © 2012 by AAN Enterprises, Inc.. All rights reserved. Print ISSN: 0028-3878. Online ISSN: 1526-632X.

