

# Pearls & Oysters: Ocular ischemic syndrome

Roberto Fernandez-  
Torrón, MD\*  
Jose-Alberto Palma, MD\*  
Inmaculada Pagola, MDCorrespondence & reprint  
requests to Dr. Palma:  
jpalmaca@unav.es**PEARL**

- The ocular ischemic syndrome (OIS) comprises a spectrum of signs that result from chronic ocular hypoperfusion as a consequence of severe carotid occlusive disease. Its diagnosis may be difficult due to the variability of presentations, which comprises unilateral visual loss, including light-induced amaurosis, and eye pain.

**OY-STER**

- Diabetic retinopathy and central retinal vein occlusion are the most likely conditions to be confused with OIS. The 5-year-mortality for patients with OIS is 40%. Thus, the establishment of an accurate diagnosis is crucial, not only to improve the visual prognosis, but also to prevent mortality.

**CASE REPORT** A 46-year-old man with a 60-pack-year smoking history, dyslipidemia, and migraine without aura had a cervical lateral acceleration/deceleration injury due to a motor vehicle accident while driving his car. No neurologic deficits were noticed within the next days. Ten days later, his right eye became gradually red, with ipsilateral lacrimation and ocular pain. Ophthalmoscopic examination showed a right episcleral vascular congestion without pupil abnormalities. Intraocular pressure (IOP) was within normal limits. The patient was diagnosed with uveitis, and topical treatment with dexamethasone and cyclopentolate (a long-acting cycloplegic) was prescribed, with initial improvement of the symptoms. Fifteen days later, the patient started experiencing episodes of right eye amaurosis that lasted for few seconds, triggered by exposure to bright light and postural changes. Initially, these episodes were transient but throughout the next weeks they became increasingly constant. Eventually, the patient developed a severe decrease in visual acuity. Concurrently, the pain reappeared in

the right eye, becoming a dull, constant ache, and radiating to the orbit and upper face. The pain worsened in the upright position, and did not improve with topical dexamethasone.

Five months after the vehicle accident, the patient presented to our clinic. Ocular movements were normal. Ophthalmoscopic examination revealed corneal edema, episcleral injection, and rubeosis iridis (abnormal neovascularization in the surface of the iris) in the right eye (figure 1A). A right Marcus-Gunn pupil was present. Visual acuity examination was 20/20 in the left eye, but he was only able to count fingers with the right eye. Funduscopy revealed small hemorrhages in the right retina (figure 1B). IOP was increased in the right eye (24 mm Hg) and normal in the left eye (18 mm Hg). The rest of the neurologic examination was unremarkable.

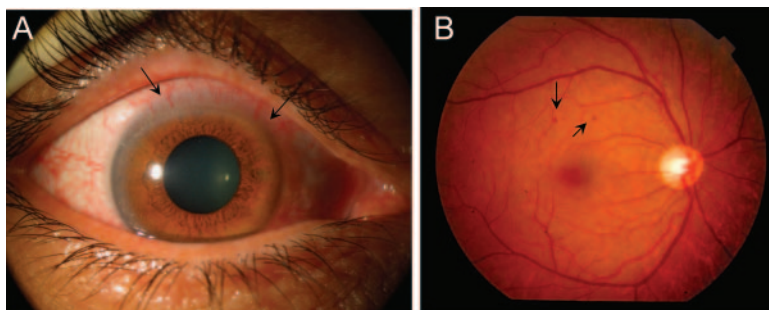
Complete blood count and coagulation tests were normal. Duplex carotid ultrasonography revealed occlusion of the initial portion of the right common carotid artery. Peak systolic velocity of the left internal carotid artery was increased (146 cm/s). Right ophthalmic artery flow was reversed and increased (125 cm/s). Transcranial Doppler ultrasound showed a reversed flow in the A1 segment of the right anterior cerebral artery. Right middle cerebral artery flow did not change with Valsalva maneuver. A brain magnetic resonance angiography confirmed the occlusion of the right common carotid artery, showing no other abnormalities. As the carotid occlusion did not fully explain the eye pain and visual loss, and to rule out other causes (i.e., arteriovenous malformations or fistulas), an arterial angiography was performed, which verified the presence of occlusion (figure 2A) and revealed an increased collateral vascularization in the right periocular region (figure 2B); thus the diagnosis of OIS was made. He was prescribed treatment with subcutaneous enoxaparin 120 mg/day, and oral prednisone 30 mg/day with dose reduction by 10 mg per week. He later underwent panretinal photocoagulation. By 6 months, the pain had resolved, and

\*These authors contributed equally to this work.

From the Department of Neurology (R.F.-T., J.-A.P., I.P.), University Clinic of Navarra, Pamplona, Spain.

Go to [Neurology.org](http://Neurology.org) for full disclosures. Disclosures deemed relevant by the authors, if any, are provided at the end of this article.

**Figure 1** Ocular findings

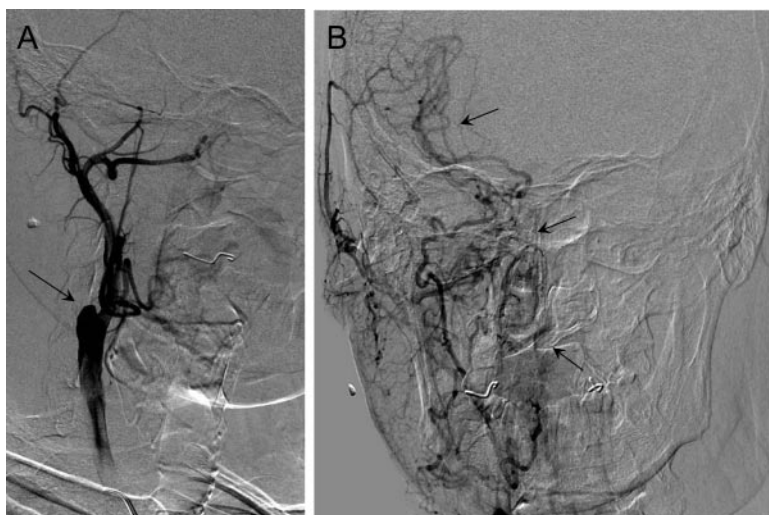


(A) Ophthalmoscopy of the right eye reveals corneal edema, conjunctival episcleral injection, and rubeosis iridis visible in the upper border of the iris (arrows). (B) Funduscopic examination reveals small dot-blot midperipheral retinal hemorrhages (arrows) probably resulting from leakage from the small retinal vessels that have had ischemic endothelial damage.

the vision loss remained stable. IOP had improved in the right eye (20 mm Hg) and remained unchanged in the left eye (18 mm Hg). Anticoagulant treatment was then switched to aspirin 100 mg/day.

**DISCUSSION** OIS is a potentially blinding and underdiagnosed disorder that arises in the context of chronic arterial hypoperfusion of the eye.<sup>1</sup> OIS most frequently results from hemodynamically significant internal carotid artery occlusion, as the ophthalmic artery is the first branch of the carotid artery and the main arterial source of the eye.<sup>2</sup> Failure to recognize and appropriately treat OIS can result in serious consequences, as the 5-year mortality rate for patients with OIS is 40%, mainly due to stroke or myocardial infarction.<sup>3</sup>

**Figure 2** Selective carotid arteriography



(A) Arterial angiography (sagittal view) reveals a complete occlusion of the right internal carotid artery origin (arrow). (B) The antero-posterior view shows a remarkable neovascularization with collateral branches arising from the external carotid artery circulation and involving the right retroocular and meningeal regions (arrows).

OIS commonly affects men with a mean age of 60 years and a history of vascular risk factors, including hypertension, diabetes, dyslipidemia, and ischemic heart disease.<sup>3</sup> Patients with OIS typically present with eye pain and decreased visual acuity. Although most patients complain of gradual vision loss, sudden blindness or amaurosis fugax, particularly light-induced amaurosis, can also occur.<sup>4,5</sup> Ophthalmoscopic findings, including conjunctival hyperemia, retinal hemorrhages, neovascular glaucoma, and macular edema, are consequences of the ocular hypoperfusion.<sup>6</sup> Although OIS only develops when the internal carotid stenosis is 90% or greater, almost 5% of patients with stenosis will develop OIS at some point in their lifetime.<sup>7</sup> The pathophysiology of OIS is related to the internal carotid artery stenosis and hypoperfusion of the ocular structures, which results in the emergence of collateral neovascularization.

There is no standardized treatment for OIS. Recognition of the underlying cause (i.e., occlusion of the carotid artery) is the chief step. When feasible, carotid endarterectomy or carotid stenting can be performed, but only if the obstruction is less than 99%.<sup>8,9</sup> For total carotid occlusion, including patients with carotid dissection, antiplatelet or anticoagulation treatment is favored. Carotid revascularization is not recommended for patients with chronic total carotid occlusion.<sup>8,9</sup> Chronic retinal and choroidal circulatory impairments in OIS may require treatment with panphotocoagulation to prevent neovascularization. Other therapies, including bevacizumab for neovascular glaucoma,<sup>4</sup> and calcium-channel blockers to prevent vasospasm,<sup>10</sup> may be useful in selected patients.

In this case, the onset of OIS and the neck trauma were temporally related. Hence, we hypothesize that a right carotid dissection, in a patient with previous vascular risk factors, may have produced the occlusion of the internal carotid artery. The internal carotid occlusion contributed to the genesis of collateral branches arising from the external carotid artery. The decrease of the ophthalmic blood flow led to retinal hypoxia, neovascular glaucoma, eye pain, and, finally, visual loss.

OIS represents a diagnostic challenge and should be considered in all patients with rapid unilateral vision loss and ocular pain.

#### AUTHOR CONTRIBUTIONS

Drafting/revising the manuscript for content: R.F.-T., J.-A.P., I.P. Study concept or design: R.F.-T., J.-A.P. Analysis or interpretation of data: R.F.-T., J.-A.P. Acquisition of data: R.F.-T., J.-A.P.

#### ACKNOWLEDGMENT

The authors thank Dr. E. Martínez-Vila, MD, PhD, Director of the Department of Neurology of the University Clinic of Navarra, for his advice, guidance, and assistance regarding this case.

## DISCLOSURE

The authors report no disclosures relevant to the manuscript. **Go to [Neurology.org](http://Neurology.org) for full disclosures.**

## REFERENCES

1. Mendrinos E, Machinis TG, Pournaras CJ. Ocular ischemic syndrome. *Surv Ophthalmol* 2010;55:2–34.
2. Foncea Beti N, Mateo I, Díaz La Calle V, Ruiz J, Gomez Beldarrain M, Garcia-Monco JC. The ocular ischemic syndrome. *Clin Neurol Neurosurg* 2003;106:60–62.
3. Sivalingam A, Brown GC, Magargal LE, Menduke H. The ocular ischemic syndrome: II: mortality and systemic morbidity. *Int Ophthalmol* 1989;13:187–191.
4. Amselem L, Montero J, Diaz-Llopis M, et al. Intravitreal bevacizumab (Avastin) injection in ocular ischemic syndrome. *Am J Ophthalmol* 2007;144:122–124.
5. Kaiboriboon K, Piriawat P, Selhorst JB. Light-induced amaurosis fugax. *Am J Ophthalmol* 2001;131:674–676.
6. Hazin R, Daoud YJ, Khan F. Ocular ischemic syndrome: recent trends in medical management. *Curr Opin Ophthalmol* 2009;20:430–433.
7. Kawaguchi S, Sakaki T, Iwahashi H, et al. Effect of carotid artery stenting on ocular circulation and chronic ocular ischemic syndrome. *Cerebrovasc Dis* 2006;22:402–408.
8. Kawaguchi S, Okuno S, Sakaki T, Nishikawa N. Effect of carotid endarterectomy on chronic ocular ischemic syndrome due to internal carotid artery stenosis. *Neurosurgery* 2001;48:328–332.
9. Brott TG, Halperin JL, Abbara S, et al. ASA/ACCF/AHA/AANN/AANS/ACR/ASNR/CNS/SAIP/SCAI/SIR/SNIS/SVM/SVS guideline on the management of patients with extracranial carotid and vertebral artery disease: executive summary: a report of the American College of Cardiology Foundation/American Heart Association Task Force on practice guidelines, and the American Stroke Association, American Association of Neuroscience Nurses, American Association of Neurological Surgeons, American College of Radiology, American Society of Neuroradiol, Congress of Neurological Surgeons, Society of Atherosclerosis Imaging and Prevention, Society for Cardiovascular Angiography and Interventions, Society of Interventional Radiology, Society of NeuroInterventional Surgery, Society for Vascular Medicine, and Society for Vascular Surgery. *Stroke* 2011;42:e420–e463.
10. Winterkorn JM, Beckman RL. Recovery from ocular ischemic syndrome after treatment with verapamil. *J Neuroophthalmol* 1995;15:209–211.

# Neurology<sup>®</sup>

## Pearls & Oy-sters: Ocular ischemic syndrome

Roberto Fernandez-Torron, Jose-Alberto Palma and Inmaculada Pagola

*Neurology* 2012;79:e92-e94

DOI 10.1212/WNL.0b013e3182698d14

**This information is current as of September 10, 2012**

<b>Updated Information &amp; Services</b>	including high resolution figures, can be found at: <a href="http://n.neurology.org/content/79/11/e92.full">http://n.neurology.org/content/79/11/e92.full</a>
<b>References</b>	This article cites 10 articles, 1 of which you can access for free at: <a href="http://n.neurology.org/content/79/11/e92.full#ref-list-1">http://n.neurology.org/content/79/11/e92.full#ref-list-1</a>
<b>Citations</b>	This article has been cited by 1 HighWire-hosted articles: <a href="http://n.neurology.org/content/79/11/e92.full##otherarticles">http://n.neurology.org/content/79/11/e92.full##otherarticles</a>
<b>Subspecialty Collections</b>	This article, along with others on similar topics, appears in the following collection(s): <b>All Pain</b> <a href="http://n.neurology.org/cgi/collection/all_pain">http://n.neurology.org/cgi/collection/all_pain</a> <b>Other cerebrovascular disease/ Stroke</b> <a href="http://n.neurology.org/cgi/collection/other_cerebrovascular_disease__stroke">http://n.neurology.org/cgi/collection/other_cerebrovascular_disease__stroke</a> <b>Retina</b> <a href="http://n.neurology.org/cgi/collection/retina">http://n.neurology.org/cgi/collection/retina</a> <b>Visual loss</b> <a href="http://n.neurology.org/cgi/collection/visual_loss">http://n.neurology.org/cgi/collection/visual_loss</a>
<b>Permissions &amp; Licensing</b>	Information about reproducing this article in parts (figures, tables) or in its entirety can be found online at: <a href="http://www.neurology.org/about/about_the_journal#permissions">http://www.neurology.org/about/about_the_journal#permissions</a>
<b>Reprints</b>	Information about ordering reprints can be found online: <a href="http://n.neurology.org/subscribers/advertise">http://n.neurology.org/subscribers/advertise</a>

*Neurology*® is the official journal of the American Academy of Neurology. Published continuously since 1951, it is now a weekly with 48 issues per year. Copyright © 2012 by AAN Enterprises, Inc.. All rights reserved. Print ISSN: 0028-3878. Online ISSN: 1526-632X.

