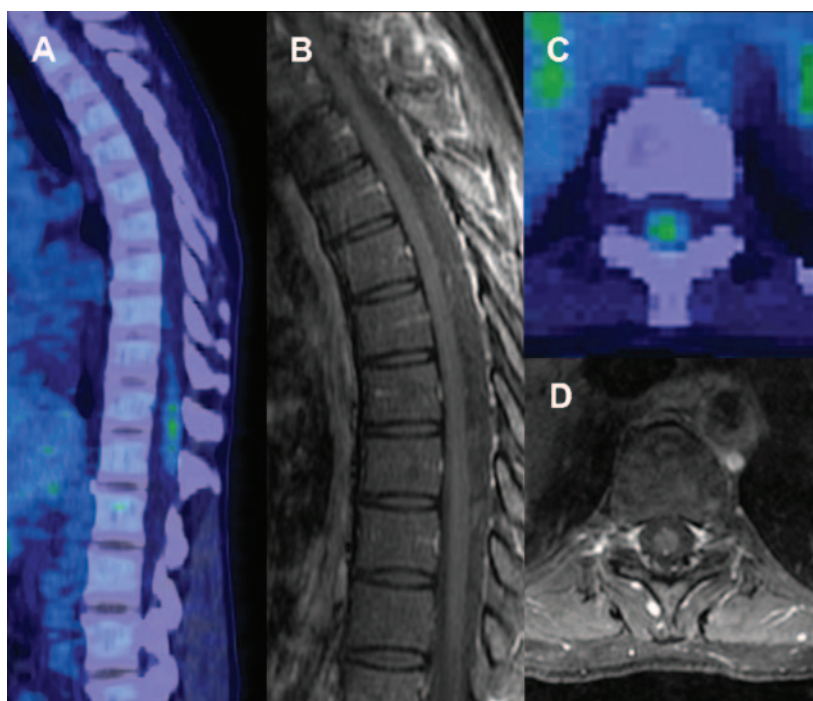


MRI and PET imaging discordance in neurosarcoidosis

Figure Thoracic spinal cord imaging



PET reveals moderate FDG activity at T9 to T12 in longitudinal (A) and axial images (C). Normal MRI of thoracolumbar spinal cord in T1 gadolinium contrast images in longitudinal (B) and T10 axial images (D).

A healthy 43-year-old woman presented with bandlike abdominal pressure and urinary frequency. Neurologic examination was normal. Chest CT showed mediastinal adenopathy with correlated FDG-PET hypermetabolism; biopsy demonstrated noncaseating granuloma consistent with sarcoidosis. Spinal involvement was suspected because of FDG-PET activity at T9–T12 (figure, A and C), and confirmed with CSF lymphocytic pleocytosis (26 cells/ μ L). Gadolinium-enhanced MRI of the thoracolumbar spinal cord was normal (figure, B and D; T2 not shown); brain MRI was not obtained. The preferred imaging modality for neurosarcoidosis is gadolinium-enhanced MRI.¹ The FDG-PET signal without MRI correlate in this case suggests that FDG-PET may provide a more sensitive early test for neurosarcoidosis.²

Josephine F. Huang, MD, Allen J. Aksamit, MD, Nathan P. Staff, MD, PhD, Rochester, MN

Author contributions: Drs. Huang and Staff drafted the manuscript. Dr. Aksamit provided revisions for the final draft.

The authors report no disclosures relevant to the manuscript. Go to Neurology.org for full disclosures.

Correspondence & reprint requests to Dr. Staff: staff.nathan@mayo.edu

1. Sherman JL, Stern BJ. Sarcoidosis of the CNS: comparison of unenhanced and enhanced MR images. *AJNR Am J Neuroradiol* 1990;11:915.
2. Dubey N, Miletich RS, Wasay M, Mechtler LL, Bakshi R. Role of fluorodeoxyglucose positron emission tomography in the diagnosis of neurosarcoidosis. *J Neurol Sci* 2002;205:77–81.

Neurology[®]

MRI and PET imaging discordance in neurosarcoidosis

Josephine F. Huang, Allen J. Aksamit and Nathan P. Staff

Neurology 2012;79;1070

DOI 10.1212/WNL.0b013e3182684672

This information is current as of September 3, 2012

Updated Information & Services	including high resolution figures, can be found at: http://n.neurology.org/content/79/10/1070.full
References	This article cites 2 articles, 1 of which you can access for free at: http://n.neurology.org/content/79/10/1070.full#ref-list-1
Subspecialty Collections	This article, along with others on similar topics, appears in the following collection(s): All Imaging http://n.neurology.org/cgi/collection/all_imaging All Medical/Systemic disease http://n.neurology.org/cgi/collection/all_medical_systemic_disease MRI http://n.neurology.org/cgi/collection/mri PET http://n.neurology.org/cgi/collection/pet
Permissions & Licensing	Information about reproducing this article in parts (figures, tables) or in its entirety can be found online at: http://www.neurology.org/about/about_the_journal#permissions
Reprints	Information about ordering reprints can be found online: http://n.neurology.org/subscribers/advertise

Neurology® is the official journal of the American Academy of Neurology. Published continuously since 1951, it is now a weekly with 48 issues per year. Copyright Copyright © 2012 by AAN Enterprises, Inc.. All rights reserved. Print ISSN: 0028-3878. Online ISSN: 1526-632X.

