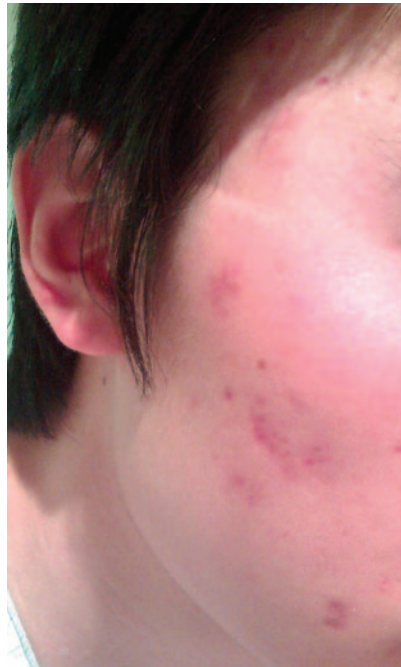

# Teaching NeuroImages: MRI in Ramsay-Hunt syndrome after trigeminal zoster

Donghoon Oh, MD, MS  
Seong-Ho Park, MD,  
PhD

Address correspondence and  
reprint requests to Dr. Seong-Ho  
Park, Department of Neurology,  
Seoul National University College  
of Medicine, Seoul National  
University Bundang Hospital,  
300 Gumi-dong, Bundang-gu,  
Seongnam-si, Gyeonggi-do, 463-  
707, South Korea  
nrpsh@snu.ac.kr

**Figure 1** Photograph of patient with right facial  
mandibular distribution zoster

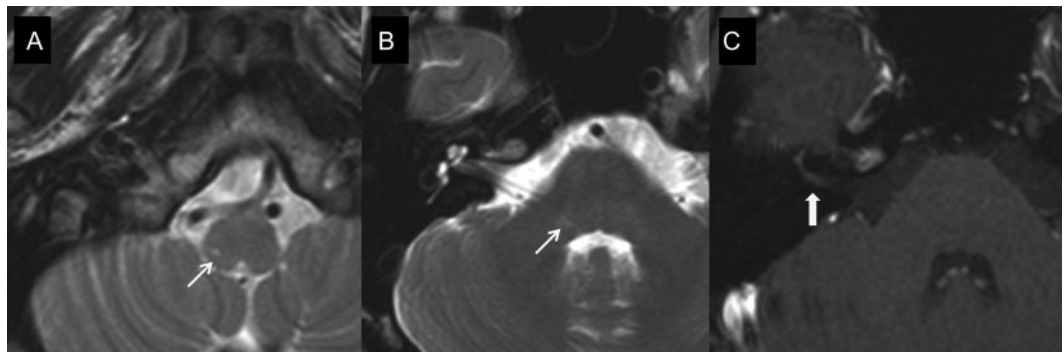


A 22-year-old man developed painful tongue swelling, a right facial rash, and right lower motor neuron facial palsy over 2 weeks. On examination he had a vesicular rash in a mandibular distribution and on the concha of the right earlobe, and right peripheral facial palsy (figure 1). T2-weighted MRI revealed high signal intensity in the spinal trigeminal tract (figure 2, A and B), and T1-weighted gadolinium-enhanced MRI revealed right facial nerve enhancement in the labyrinthine segment (figure 2C). MRI findings of spinal trigeminal nucleus and tract involvement in trigeminal zoster,<sup>1</sup> and of facial nerve enhancement in Ramsay-Hunt syndrome,<sup>2</sup> have been reported. Our patient developed trigeminal zoster and Ramsay-Hunt syndrome sequentially, and we confirmed corresponding abnormalities on MRI.

## REFERENCES

1. Aribandi M, Aribandi L. MRI of trigeminal zoster. *Neurology* 2005;65:1812.
2. Tada Y, Aoyagi M, Tojima H, et al. Gd-DTPA enhanced MRI in Ramsay Hunt syndrome. *Acta Otolaryngol Suppl* 1994;511:170–174.

**Figure 2** MRIs of the patient



Axial T2-weighted MRIs show high signal intensity in the right lower pons and medulla posteriorly and laterally (A, B) (arrows) corresponding to the location of the spinal trigeminal tract. Axial T1-weighted gadolinium-enhanced MRI reveals right facial nerve enhancement in the labyrinthine segment (C) (arrow).

From the Department of Neurology, Seoul National University Bundang Hospital, South Korea.

*Disclosure:* The authors report no disclosures.

# Neurology<sup>®</sup>

## Teaching NeuroImages: MRI in Ramsay-Hunt syndrome after trigeminal zoster

Donghoon Oh and Seong-Ho Park

*Neurology* 2010;74:e33

DOI 10.1212/WNL.0b013e3181d25b4a

**This information is current as of March 1, 2010**

<b>Updated Information &amp; Services</b>	including high resolution figures, can be found at: <a href="http://n.neurology.org/content/74/9/e33.full">http://n.neurology.org/content/74/9/e33.full</a>
<b>References</b>	This article cites 2 articles, 1 of which you can access for free at: <a href="http://n.neurology.org/content/74/9/e33.full#ref-list-1">http://n.neurology.org/content/74/9/e33.full#ref-list-1</a>
<b>Subspecialty Collections</b>	This article, along with others on similar topics, appears in the following collection(s): <b>All Clinical Neurology</b> <a href="http://n.neurology.org/cgi/collection/all_clinical_neurology">http://n.neurology.org/cgi/collection/all_clinical_neurology</a> <b>MRI</b> <a href="http://n.neurology.org/cgi/collection/mri">http://n.neurology.org/cgi/collection/mri</a> <b>Viral infections</b> <a href="http://n.neurology.org/cgi/collection/viral_infections">http://n.neurology.org/cgi/collection/viral_infections</a>
<b>Permissions &amp; Licensing</b>	Information about reproducing this article in parts (figures, tables) or in its entirety can be found online at: <a href="http://www.neurology.org/about/about_the_journal#permissions">http://www.neurology.org/about/about_the_journal#permissions</a>
<b>Reprints</b>	Information about ordering reprints can be found online: <a href="http://n.neurology.org/subscribers/advertise">http://n.neurology.org/subscribers/advertise</a>

*Neurology*® is the official journal of the American Academy of Neurology. Published continuously since 1951, it is now a weekly with 48 issues per year. Copyright . All rights reserved. Print ISSN: 0028-3878. Online ISSN: 1526-632X.

