

# Teaching NeuroImages:

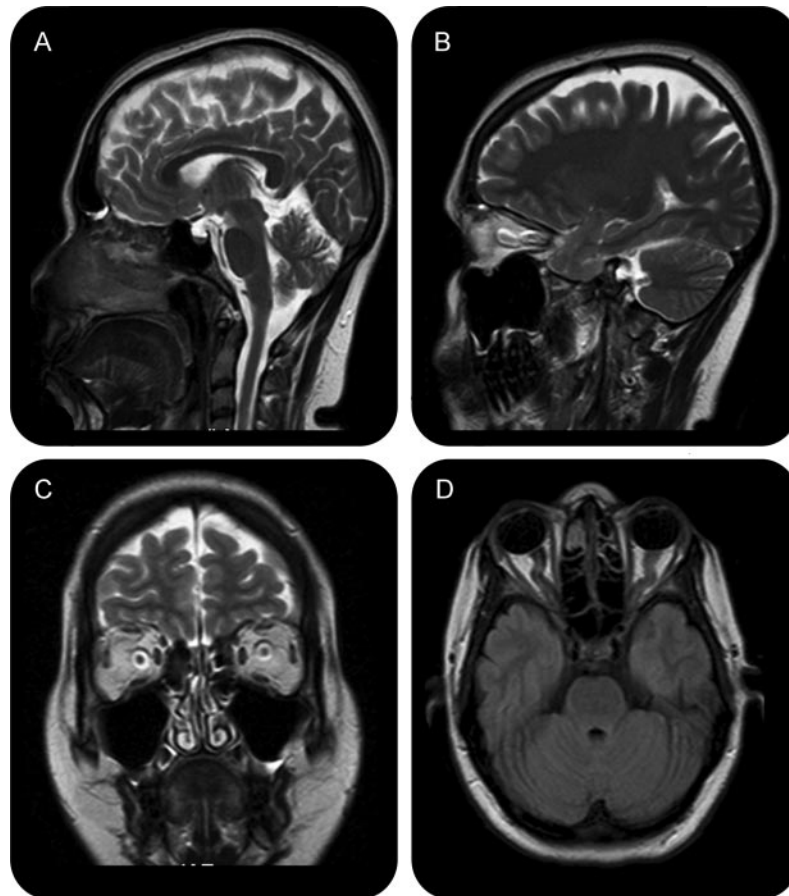
## Idiopathic intracranial hypertension

### MRI features

Haseeb Hassan, MD  
Abhijit Das, MD  
Neeraj N. Baheti, MD  
Ashalatha Radhakrishnan,  
DM

Address correspondence and  
reprint requests to Dr. Abhijit  
Das, Department of Neurology,  
Sree Chitra Tirunal Institute for  
Medical Sciences and  
Technology, Trivandrum, India  
abhijit.neuro@gmail.com

**Figure** MRI features of idiopathic intracranial hypertension



(A, B) Sagittal T2 MRI (1.5 Tesla) showing partially empty sella turcica and buckling of optic nerves. (C) Coronal T2 images showing dilated perioptic CSF spaces. (D) Axial fluid-attenuated inversion recovery images showing buckling of bilateral optic nerves and flattening of the posterior aspect of the optic globe.

A 31-year-old woman presented with insidious onset headache, pulsatile subjective bruit, and bilateral vision loss. She was obese with bilateral papilledema, visual acuity of 20/40, and normal visual fields without any localizing neurologic signs. CSF opening pressure was 290 mm of water with normal composition. MRI showed characteristic features<sup>1</sup> (figure) without structural lesion or hydrocephalus. Her magnetic resonance venogram was normal, establishing the diagnosis of idiopathic intracranial hyper-

tension (IIH).<sup>2</sup> Although individual magnetic resonance signs lack sensitivity<sup>1</sup> in diagnosis of IIH, a combination of signs in the context of a clinical picture is very helpful.

#### REFERENCES

1. Agid R, Farb RI, Willinsky RA, et al. Idiopathic intracranial hypertension: the validity of cross-sectional neuroimaging signs. *Neuroradiology* 2006;48:521–527.
2. Friedman DI, Jacobson DM. Diagnostic criteria for idiopathic intracranial hypertension. *Neurology* 2002;59:1492–1495.

From the Department of Neurology, Sree Chitra Tirunal Institute for Medical Sciences and Technology, Trivandrum, India.

*Disclosure:* The authors report no disclosures.

# Neurology®

## Teaching *NeuroImages*: Idiopathic intracranial hypertension: MRI features

Haseeb Hassan, Abhijit Das, Neeraj N. Baheti, et al.

*Neurology* 2010;74:e24

DOI 10.1212/WNL.0b013e3181cff723

**This information is current as of February 15, 2010**

<b>Updated Information &amp; Services</b>	including high resolution figures, can be found at: <a href="http://n.neurology.org/content/74/7/e24.full">http://n.neurology.org/content/74/7/e24.full</a>
<b>References</b>	This article cites 2 articles, 1 of which you can access for free at: <a href="http://n.neurology.org/content/74/7/e24.full#ref-list-1">http://n.neurology.org/content/74/7/e24.full#ref-list-1</a>
<b>Subspecialty Collections</b>	This article, along with others on similar topics, appears in the following collection(s): <b>All Clinical Neurology</b> <a href="http://n.neurology.org/cgi/collection/all_clinical_neurology">http://n.neurology.org/cgi/collection/all_clinical_neurology</a> <b>All Headache</b> <a href="http://n.neurology.org/cgi/collection/all_headache">http://n.neurology.org/cgi/collection/all_headache</a> <b>All Neuro-ophthalmology</b> <a href="http://n.neurology.org/cgi/collection/all_neuroophthalmology">http://n.neurology.org/cgi/collection/all_neuroophthalmology</a> <b>Idiopathic intracranial hypertension</b> <a href="http://n.neurology.org/cgi/collection/idiopathic_intracranial_hypertension">http://n.neurology.org/cgi/collection/idiopathic_intracranial_hypertension</a> <b>MRI</b> <a href="http://n.neurology.org/cgi/collection/mri">http://n.neurology.org/cgi/collection/mri</a>
<b>Permissions &amp; Licensing</b>	Information about reproducing this article in parts (figures,tables) or in its entirety can be found online at: <a href="http://www.neurology.org/about/about_the_journal#permissions">http://www.neurology.org/about/about_the_journal#permissions</a>
<b>Reprints</b>	Information about ordering reprints can be found online: <a href="http://n.neurology.org/subscribers/advertise">http://n.neurology.org/subscribers/advertise</a>

*Neurology*® is the official journal of the American Academy of Neurology. Published continuously since 1951, it is now a weekly with 48 issues per year. Copyright . All rights reserved. Print ISSN: 0028-3878. Online ISSN: 1526-632X.

