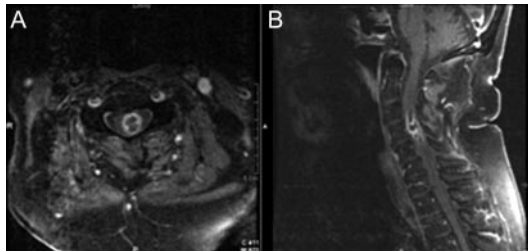


Teaching NeuroImage: Nocardial intramedullary spinal cord abscess

Lawrence M. Samkoff,
MD
Ahmad Monajati, MD
Joel L. Shapiro, MD

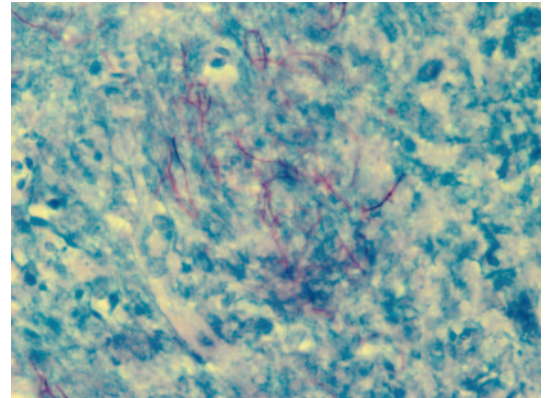
Address correspondence and
reprint requests to Dr. Lawrence
Samkoff, Department of
Neurology, University of
Rochester School of Medicine and
Dentistry, Rochester General
Hospital, 1425 Portland Avenue,
Rochester, NY 14621
lawrence.samkoff@viahealth.org

Figure 1 Gadolinium-enhanced axial (A) and sagittal (B) T1 fat-saturated MRI of the cervical spine demonstrating intramedullary abscess at the left C3-4 level, associated with enlargement of the spinal cord from C2 to C7



A 79-year-old man with ulcerative colitis on chronic prednisone therapy developed severe midcervical pain and progressive weakness of the left arm and leg over several days. This was associated with left forearm paresthesias and urinary hesitancy and incontinence. He had no cranial or bulbar symptoms. On general examination, he was afebrile but there was midcervical spine tenderness. Neurologic examination revealed normal mental status and cranial nerves; strength was 2/5 on the left, and 4/5 on the right; there was a sensory level to pain and temperature on the right to C4, with reduced proprioception in the left foot and hand; there was a left Babinski sign and a mute right plantar response. White blood cell count was $18.2 \times 10^9/L$. Blood cultures were negative. Chest CT demonstrated multiple lung nodules. Cervical spine MRI (figure 1) revealed an intramedullary ring-enhancing mass on the left at C3-4 associated with edema from C2 to C7. Open spinal cord biopsy revealed *Nocardia farcinica* abscess (figure 2). Lumbar puncture and bronchoscopy were not performed. The patient was treated with IV trimethoprim-sulfamethoxazole and dexamethasone. After 10 days, lower extremity strength improved bi-

Figure 2 Branching, filamentous, beaded bacteria identified within necrotic debris



The microorganisms were stained by GMS (silver) and Fite (modified acid fast) stains; they did not stain on Ziehl-Neelsen (conventional acid fast) or tissue gram stains. The morphologic and staining characteristics are most consistent with *Nocardia* species. Fite stain at $100\times$ (oil) is shown.

laterally. Left arm strength and sensory deficits remained unchanged. He died 8 weeks later due to cardiac arrest. No autopsy was performed.

CNS nocardiosis is usually associated with systemic nocardial infection. Although brain abscess is the most common presentation of CNS nocardiosis, rare cases of intramedullary spinal cord abscess have been reported.^{1,2} *Nocardia* abscess should be considered in immunocompromised patients with spinal cord syndromes. Expeditious tissue diagnosis and antibiotic therapy are essential to improved outcomes.

REFERENCES

1. Mukunda BN, Shekar R, Bass S. Solitary spinal intramedullary abscess caused by *Nocardia asteroides*. South Med J 1999;92:1223-1224.
2. Durmaz R, Metin AA, Durmaz G, et al. Multiple nocardial abscess of cerebrum, cerebellum, and spinal cord, causing quadriplegia. Clin Neuro Neurosurg 2001;103:59-62.

From the Department of Neurology (L.M.S.), University of Rochester School of Medicine and Dentistry, and Departments of Radiology (A.M.) and Pathology (J.L.S.), Rochester General Hospital, Rochester, NY.

Disclosure: The authors report no disclosures.

Neurology[®]

Teaching *NeuroImage*: Nocardial intramedullary spinal cord abscess

Lawrence M. Samkoff, Ahmad Monajati and Joel L. Shapiro

Neurology 2008;71:e5

DOI 10.1212/01.wnl.0000317099.34987.b6

This information is current as of July 14, 2008

Updated Information & Services	including high resolution figures, can be found at: http://n.neurology.org/content/71/3/e5.full
References	This article cites 2 articles, 0 of which you can access for free at: http://n.neurology.org/content/71/3/e5.full#ref-list-1
Subspecialty Collections	This article, along with others on similar topics, appears in the following collection(s): Abscess http://n.neurology.org/cgi/collection/abscess Spinal cord infection http://n.neurology.org/cgi/collection/spinal_cord_infection
Permissions & Licensing	Information about reproducing this article in parts (figures, tables) or in its entirety can be found online at: http://www.neurology.org/about/about_the_journal#permissions
Reprints	Information about ordering reprints can be found online: http://n.neurology.org/subscribers/advertise

Neurology® is the official journal of the American Academy of Neurology. Published continuously since 1951, it is now a weekly with 48 issues per year. Copyright . All rights reserved. Print ISSN: 0028-3878. Online ISSN: 1526-632X.

