

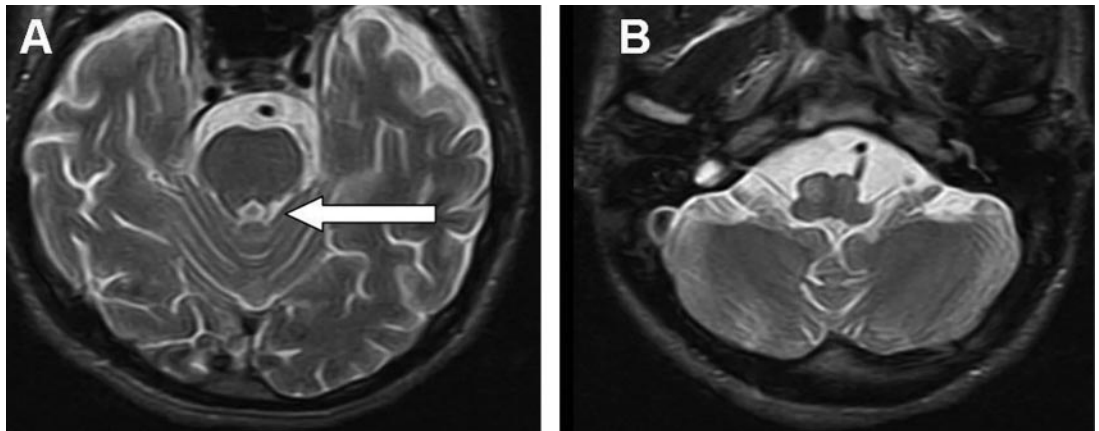
Teaching NeuroImage: Posttraumatic palatal tremor



Pranshu Sharma, MD
Muneer Eesa, MD
Alexandre Y. Poppe,
MD, FRCPC
Mayank Goyal, MD,
FRCPC

Address correspondence and
reprint requests to Dr. Pranshu
Sharma, Department of
Diagnostic Imaging, Foothills
Medical Centre, 1403-29 St NW
Calgary, AB T2N 2T9, Canada
pranshu.sharma@calgaryhealthregion.ca

Figure T2-weighted axial MRIs showing left superior cerebellar peduncle atrophy due to remote diffuse axonal injury (A, arrow) resulting in enlargement and increased signal intensity of the right inferior olivary nucleus suggesting hypertrophic olivary degeneration (B)



A 56-year-old man with head injury, loss of consciousness, and normal head CT 6 weeks prior presented with persistent headache. No neurologic deficit was elicited on examination except for involuntary rhythmic movements of the soft palate, from which he was asymptomatic (video on the *Neurology*[®] Web site at www.neurology.org). In particular, he did not complain of ear clicks, and no treatment was offered. MRI showed foci of remote diffuse axonal injury including the left superior cerebellar peduncle (figure, A). The right inferior olivary nucleus was enlarged and hyperintense on T2-weighted images (figure, B).

Symptomatic palatal tremor occurs due to trans-synaptic hypertrophic degeneration of the inferior olivary nucleus secondary to lesions involving the contralateral dentate nucleus, superior cerebellar peduncle, or ipsilateral central tegmental tract within the brainstem (Guillain-Mollaret triangle).¹

REFERENCE

1. Goyal M, Versnick E, Tuite P, et al. Hypertrophic olivary degeneration: metaanalysis of the temporal evolution of MR findings. *Am J Neuroradiol* 2000;21:1073-1077.

Supplemental data at
www.neurology.org

From the Department of Diagnostic Imaging (P.S., M.E., M.G.) and Calgary Stroke Program, Department of Clinical Neurosciences, University of Calgary (A.Y.P.), Foothills Medical Centre, Alberta, Canada.

Disclosure: The authors report no disclosures.

Neurology[®]

Teaching NeuroImage: Posttraumatic palatal tremor
Pranshu Sharma, Muneer Eesa, Alexandre Y. Poppe, et al.
Neurology 2008;71;e30
DOI 10.1212/01.wnl.0000326578.18675.3a

This information is current as of September 22, 2008

| | |
|---|--|
| Updated Information & Services | including high resolution figures, can be found at: http://n.neurology.org/content/71/13/e30.full |
| Supplementary Material | Supplementary material can be found at: http://n.neurology.org/content/suppl/2008/09/21/71.13.e30.DC1 |
| References | This article cites 1 articles, 0 of which you can access for free at: http://n.neurology.org/content/71/13/e30.full#ref-list-1 |
| Subspecialty Collections | This article, along with others on similar topics, appears in the following collection(s): Clinical neurology examination http://n.neurology.org/cgi/collection/clinical_neurology_examination MRI http://n.neurology.org/cgi/collection/mri Myoclonus http://n.neurology.org/cgi/collection/myoclonus Tremor http://n.neurology.org/cgi/collection/tremor |
| Permissions & Licensing | Information about reproducing this article in parts (figures, tables) or in its entirety can be found online at: http://www.neurology.org/about/about_the_journal#permissions |
| Reprints | Information about ordering reprints can be found online: http://n.neurology.org/subscribers/advertise |

Neurology® is the official journal of the American Academy of Neurology. Published continuously since 1951, it is now a weekly with 48 issues per year. Copyright . All rights reserved. Print ISSN: 0028-3878. Online ISSN: 1526-632X.

