

# Pearls & Oy-sters: False positives in short-segment nerve conduction studies due to ulnar nerve dislocation

B.J. Kim, MD, PhD  
S.B. Koh, MD, PhD  
K.W. Park, MD, PhD  
S.J. Kim, MD, PhD  
J.S. Yoon, MD, PhD

Address correspondence and  
reprint requests to Dr. Joon  
Shik Yoon, Department of  
Rehabilitation Medicine, Korea  
University Guro Hospital,  
Korea University College of  
Medicine, 80, Guro-dong,  
Guro-gu, Seoul, 152-703, Korea  
rehab46@korea.ac.kr

## ABSTRACT

The possibility that a technical error may occur during nerve conduction studies due to ulnar nerve dislocation when the elbow is flexed has recently been suggested. We investigated normal volunteers using ultrasonography to observe the effects of ulnar nerve dislocation during elbow flexion on short-segment nerve conduction studies. We found significant conduction block in all of the subjects with ulnar nerve dislocation, and the finding was defined as a technical error caused by volume conduction. The results of the present study suggest that caution should be exercised when interpreting the results of short-segment nerve conduction studies at the across-elbow segment due to the possibility of technical error induced by ulnar nerve dislocation. *GLOSSARY* NCS = nerve conduction study; S-NCS = short-segment NCS; UNE = ulnar neuropathy at the elbow. *Neurology*® 2008;70:e9-e13

A nerve conduction study (NCS) is the most valuable diagnostic tool in patients with ulnar neuropathy at the elbow (UNE). However, the possibility that a technical error induced by ulnar nerve dislocation may occur when the elbow is flexed has recently been suggested.<sup>1</sup> Indeed, the position of the elbow may have a significant influence on the calculated ulnar nerve conduction velocity across the elbow,<sup>2</sup> and when the elbow is extended, it is thought that the ulnar nerve may become loose or redoubled in the ulnar groove and that surface measurements do not accurately reflect the true distance of the underlying nerve.<sup>2,3</sup> Elbow flexion may stretch the nerve; therefore, the measurement of the ulnar groove distance is a more accurate reflection of the distance along the nerve in the ulnar groove. The recommended position of the elbow during ulnar NCS is flexion at 90 or 135 degrees in order to straighten the ulnar nerve.<sup>4</sup> However, significant technical error may be caused by ulnar nerve displacement when the elbow is flexed.<sup>1</sup>

NCS with short-segment interval stimulations has been commonly used to increase the sensitivity for very focal lesions, because the effect of the abnormally slow segment is progressively diluted as more and more normal segments are included in the examination.<sup>5</sup> A short-segment NCS (S-NCS) can be performed by stimulating the nerve at 2-cm intervals across the elbow in the flexed position.<sup>6</sup> A significant conduction delay or focal change in amplitude or waveform morphology across a segment is generally considered abnormal; however, ulnar nerve displacement by elbow flexion may cause a more significant technical error in S-NCS than in routine NCS at the across-elbow segment.

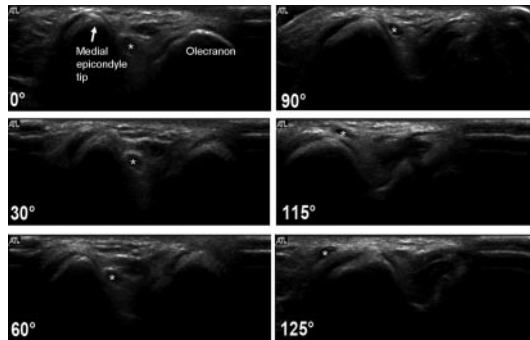
In the present study, we investigated the effects of ulnar nerve displacement on S-NCS at the across-elbow segment. We also measured the angle of the elbow when the ulnar nerve was dislocated by elbow flexion.

**METHODS Participants and evaluation.** We studied 234 elbows from 117 healthy volunteers (52 men, 65 women), ages 20 to 50 years (mean age, 30.4 y), who had normal NCS results in their upper extremities. Elbow flexion at approximately 135° was used for ulnar NCS in all subjects. None of the participants had any history or symptoms of elbow pain or trauma,

From the Departments of Neurology (B.J.K., S.B.K., K.W.P.) and Rehabilitation Medicine (S.J.K., J.S.Y.), College of Medicine, Korea University, Seoul.

*Disclosure:* The authors report no conflicts of interest.

**Figure 1** Angle of the elbow when the ulnar nerve was dislocated



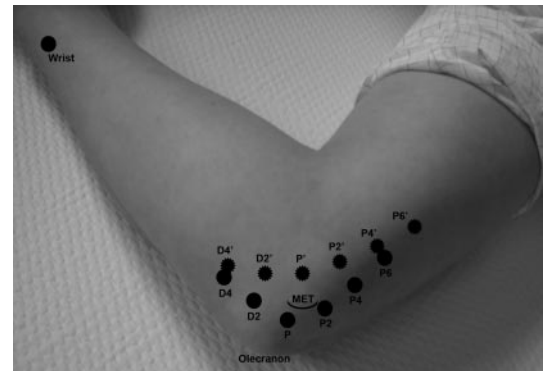
The ulnar nerve (\*) moved onto the tip of the medial epicondyle when the elbow was flexed and finally dislocated at 125 degrees of flexion.

entrapment neuropathy, or systemic disease. Approval from the hospital institutional review board was obtained prior to conducting the study. Written informed consent, in which the potential risks of ultrasonography were outlined, was obtained from the participants before the procedure.

**Real-time ultrasonographic study.** A 7.5 to 12 MHz linear transducer (5000 System HDI; Philips Medical Systems NA, WA) was applied on the line between the medial epicondyle and olecranon of subjects lying supine on an examining table. We used the B mode to view the ulnar nerve in the postcondylar groove between the medial epicondyle and olecranon and used the color Doppler mode to differentiate arteries. A baseline nerve location was determined at zero degrees of elbow flexion, and we observed whether the ulnar nerve was displaced at any angle during elbow flexion using real-time ultrasonography. We classified the position of the ulnar nerve (during elbow flexion) into one of three types according to the classification system of a previous report.<sup>7</sup> Type N (no dislocation) classification was assigned when the nerve moved anteriorly, but not to the tip of the epicondyle, during elbow flexion. The ulnar nerve position was classified as type S (subluxation) when the nerve moved onto the tip of the epicondyle. The position of the ulnar nerve was classified as type D (dislocation) when the nerve moved anteriorly beyond the tip of the epicondyle. In cases of type D, we measured the angle of the elbow using a goniometer when the ulnar nerve was dislocated (figure 1). To measure the angle, an axis of the goniometer was located on the skin of the medial epicondyle tip, and a proximal fixed arm of the goniometer was aligned parallel to the long axis of the upper arm. A distal movable arm was then attached to the medial surface of the forearm long axis. The elbow angle was defined as the angle made by the movement of the distal movable arm with forearm flexion from the extended position.

**Short-segment nerve conduction study.** S-NCSs for the ulnar nerve were performed in subjects with type S and D classifications by an electromyographer who was blind to the classification type. The S-NCSs were performed at an elbow position of approximately 135°. Prior to the S-NCS, we confirmed that none of the subjects among those with type S and D classifications had weakness in the ulnar innervated muscles or sensory changes in the fourth and fifth fingers. To achieve approximately 135° of elbow flexion in the

**Figure 2** Stimulation points for the short-segment ulnar nerve conduction study



The black dots represent the stimulation points for the ulnar nerve located in the ulnar groove (marked without prime). The ragged dots indicate the stimulation points for the dislocated ulnar nerve tracked by ultrasonography (marked with a prime). P = midpoint in the ulnar groove between the tip of the medial epicondyle and the olecranon. P2 = 2 cm proximal to point P. D2 = 2 cm distal to point P. P' = the closest ulnar nerve point from the tip of the medial epicondyle tracked by ultrasonography. MET = medial epicondyle tip.

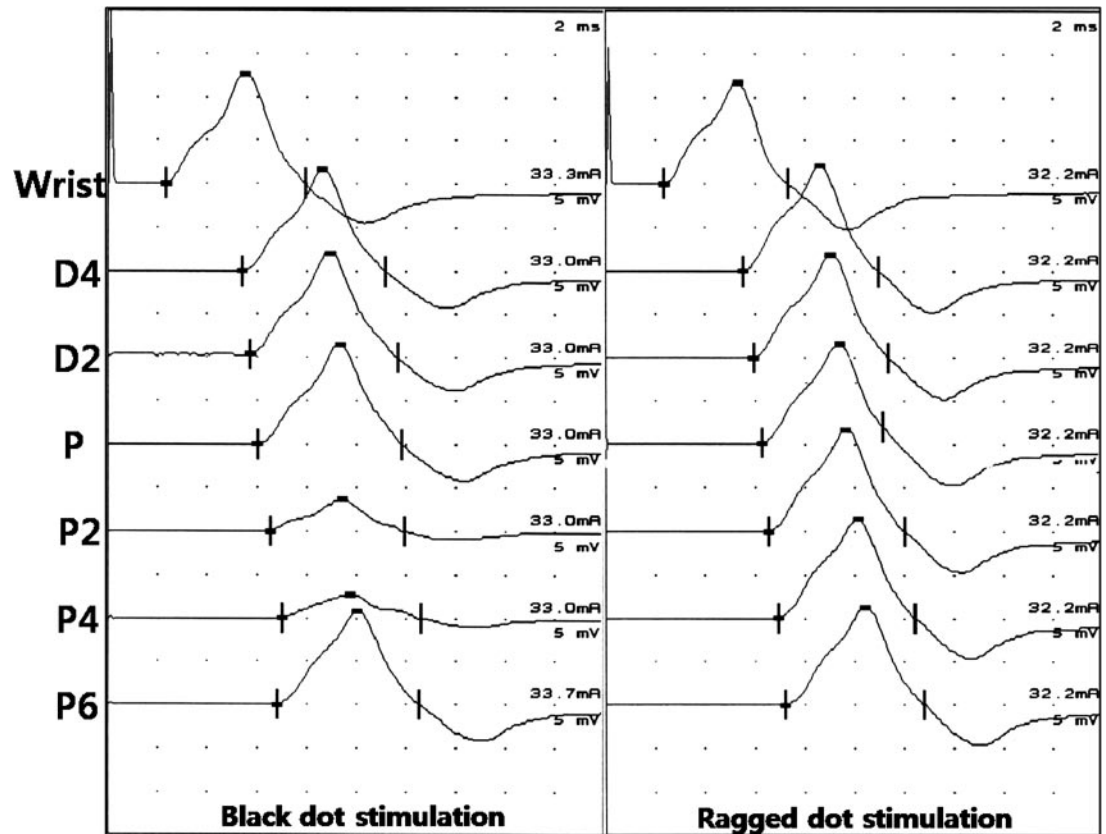
most comfortable position possible, subjects were positioned supine on an examining table and asked to abduct their upper arm to 90° and to rest it on a pillow such that the hand approached the ipsilateral ear, resulting in elbow flexion. The midpoint of the ulnar groove between the tip of the medial epicondyle and the olecranon was marked (point P; figure 2). From this point, marks were placed along the course of the ulnar nerve at 2-cm intervals from 6 cm proximal to 4 cm distal.

The ulnar nerve was stimulated with abductor digiti minimi recording at each mark. The recording electrode was placed over the belly of the abductor digiti minimi, and the reference electrode was placed over the distal tendon. A constant current stimulator (2-cm intervals between cathode and anode) and a disposable, flat-surface electrode 1 cm in diameter were used for recording. Equipment used for the study was manufactured by Nicolet Biomedical (Viking IV, Madison, WI). A sensitivity setting of 5 mV/division, a sweep speed of 2 msec/division, and a filter setting of 5 Hz to 5 KHz was maintained throughout all measurements. The skin temperature of the subjects during the study was also maintained at or above 32 °C. Before the measurements were performed, we ensured that supramaximal stimulation was achieved and that adequate pressure was applied to the stimulating electrodes in order to enable focal stimulation without spread.

Latencies were measured from the stimulus to CMAP onset, and the amplitude measurements were calculated from baseline to negative peak. A conduction delay of greater than 0.5 msec or conduction block with an amplitude reduction of 50% or more across 2-cm segments were defined as abnormal.<sup>8</sup>

After the S-NCS, the nerves that were displaced by elbow flexion were tracked using ultrasonography and marked as ragged dots when elbow flexion was at 135°. The closest point from the tip of the medial epicondyle was marked as point P'. Marks were then placed along the course of the

**Figure 3** Example of short-segment ulnar nerve conduction study



Conduction block on the point P2 with traditional site (black dots in figure 2) stimulation was transformed to normal waves by stimulation with ultrasound-guided nerve localization (ragged dots in figure 2).

tracked ulnar nerve at 2-cm intervals from 6 cm proximal to 4 cm distal to point P' (ragged dots in figure 2). The S-NCSs were performed again by stimulating the ragged dots.

**RESULTS Ultrasonography.** Ulnar nerve dislocation (Type D) occurred in 13 elbows (5.6%) of 13 subjects (8 men, 5 women). Ulnar nerve subluxation (Type S) was found in 58 elbows (24.8%) of 49 subjects (22 men, 27 women). The mean elbow angle associated with ulnar nerve dislocation was 99.8° (range 75 to 135). The ulnar nerve was dislocated at an elbow angle of less than 90° in 3 elbows; 2 elbows were at 87°, and 1 elbow was at 75°.

**Short-segment nerve conduction study.** All 13 cases of ulnar nerve dislocation at the elbow exhibited delayed latency (12 subjects; mean 0.62 msec, range 0.6 to 0.8 msec) or a conduction block around the medial epicondyle during the S-NCS with black dot stimulation. Of the 13 subjects with conduction block, the amplitude drop points were P in 6 subjects and P2 in 3 subjects; the mean amplitude drop rate in these 9 subjects was 68.9% (range 58.8 to 92.2%). The other 4 subjects showed complete conduction block (no evoked

compound muscle action potential) at point P2. One of the 4 subjects with complete conduction block showed an amplitude drop of 34% at point P. However, no abnormal findings were detected in the elbows of the subjects with ulnar nerve subluxation during elbow flexion.

The abnormal findings in the 13 elbows with ulnar nerve dislocation were transformed to normal waveforms and latencies using ragged dot stimulation (figure 3).

**DISCUSSION** The prevalence of ulnar nerve displacement in the present study was similar to the results of our previous study that showed dislocation in 3.8% and subluxation in 20.5% of subjects.<sup>1</sup> The results of these two studies showed a high percentage of ulnar nerve displacement in comparison with a previous report,<sup>9</sup> although this is probably due to the increased precision of investigation with high-resolution ultrasonography. On the other hand, the percentage of ulnar nerve displacement in the present study was low in comparison with that from another report that found ulnar nerve dislocation in 39 elbows (20%) and ulnar nerve subluxation in 53 elbows (27%)

out of 200 healthy elbows.<sup>7</sup> Considering that the report included older subjects (age 20 to 69 years) than our study (age 20 to 50 years), the higher percentage reported in that report was likely related to the loosening of soft tissue in the ulnar groove due to aging, which would result in a higher chance of ulnar nerve displacement.

UNE is the second most common upper extremity compression neuropathy<sup>10</sup>; however, the diagnosis of UNE is not straightforward. Most physicians suspect UNE when a patient complains of occasional ulnar distribution numbness and paresthesias; however, these symptoms could be caused by a variety of conditions, such as lower cervical radiculopathy, lower trunk involvement of the brachial plexus, Guyon canal palsy, and even myofascial pain syndrome. The diagnostic yield of electrodiagnosis of UNE is low, and the interpretation of the data is often quite difficult. In our previous study, we suggested the possibility of false negatives in the detection of UNE if a patient has ulnar nerve dislocation during elbow flexion.<sup>1</sup> If a patient is seen who is suspected of having UNE, but nonetheless shows normal findings in routine NCS, S-NCS could be used as one of the next steps to increase sensitivity of the diagnosis. Indeed, the results of the present study showed that the S-NCS performed with elbow flexion in patients with ulnar nerve dislocation at the elbow could lead to a significant diagnostic error. All elbows showed conduction block or significant latency delays in the ulnar nerve at the across-elbow segment, which is important, because the identification of these signs are important criteria for the diagnosis of UNE.<sup>6</sup> Therefore, significant caution is needed when using S-NCS. Although elbow flexion at 90 or 135° is recommended during NCS to straighten the ulnar nerve in the ulnar groove, the technical error induced by ulnar nerve dislocation during elbow flexion should not be overlooked. In the present study, most elbow angles when the ulnar nerves were dislocated were more than 90°. Only three elbows were at an angle less than 90°, and two of the three elbows were very close to 90°, both at an angle of 87°. This finding indicates that there is less chance of ulnar nerve dislocation during NCS at the across-elbow segment when the degree of elbow flexion is less than 90°.

To our knowledge, although there have been no studies that have reported that dislocation of the ulnar nerve predisposes a patient to ulnar neuropathy, recurring ulnar nerve dislocation at the elbow may cause bothersome symptoms in some

subjects via repeated irritation or enhanced exposure to injury. Therefore, detection of ulnar nerve dislocation using ultrasonography would be helpful in evaluating patients with normal conduction velocities in routine nerve conduction study at the across-elbow segment, despite clinical symptoms of highly suspected UNE. If ultrasonography is not available in a clinic, an alternative study could include S-NCS, which should be performed with two elbow positions, with one at less than 90 degrees and the other at full flexion. The appearance of conduction delay or block with full flexion would support either dislocation or transient compressive neurapraxia, either of which might be important in a symptomatic patient after other causes of symptoms have been excluded. Future studies are needed to investigate the reliability of this potential approach and the importance of dislocation as a predisposing factor for UNE.

S-NCS for assessment of the ulnar nerve at the across-elbow segment requires special caution due to the possibility of technical error caused by elbow position. Many laboratories use a variety of elbow angles in order to minimize measurement errors due to an ulnar nerve redundancy; however, such practices may overlook another source of artifact, especially since we observed that ulnar nerve dislocation induced by elbow overflexion could lead to significant technical error. The results of our study suggest that S-NCS at the elbow should be performed with the elbow flexed at less than 90 degrees. Future studies are needed to investigate the ideal range of the elbow angle during S-NCS in order to avoid technical error caused by the position of the elbow.

## REFERENCES

1. Kim BJ, Date ES, Lee SH, Yoon JS, Hur SY, Kim SJ. Distance measure error induced by displacement of the ulnar nerve when the elbow is flexed. *Arch Phys Med Rehabil* 2005;86:809–812.
2. Checkles NS, Russakov AD, Piero DL. Ulnar nerve conduction velocity—effect of elbow position on measurement. *Arch Phys Med Rehabil* 1971;52:362–365.
3. Nelson RM. Effects of elbow position on motor conduction velocity of the ulnar nerve. *Phys Ther* 1980;60:780–783.
4. Kimura J. Assessment of individual nerves. In: Kimura J, ed. *Electrodiagnosis in Diseases of Nerve and Muscle: Principles and Practice*, 3rd ed. New York: Oxford University Press; 2001:146.
5. Campbell WW. The value of inching techniques in the diagnosis of focal nerve lesions. Inching is a useful technique. *Muscle Nerve* 1998;21:1554–1556; discussion 1561.

6. Kanakamedala RV, Simons DG, Porter RW, Zucker RS. Ulnar nerve entrapment at the elbow localized by short segment stimulation. *Arch Phys Med Rehabil* 1988;69:959–963.
7. Okamoto M, Abe M, Shirai H, Ueda N. Morphology and dynamics of the ulnar nerve in the cubital tunnel. Observation by ultrasonography. *J Hand Surg* 2000;25:85–89.
8. Azrieli Y, Weimer L, Lovelace R, Gooch C. The utility of segmental nerve conduction studies in ulnar mononeuropathy at the elbow. *Muscle Nerve* 2003;27:46–50.
9. Childress HM. Recurrent ulnar-nerve dislocation at the elbow. *J Bone Joint Surg Am* 1956;38-A:978–984.
10. Campbell WW. Ulnar neuropathy at the elbow. *Muscle Nerve* 2000;23:450–452.

# Neurology<sup>®</sup>

## **Pearls & Oysters: False positives in short-segment nerve conduction studies due to ulnar nerve dislocation**

B. J. Kim, S. B. Koh, K. W. Park, et al.

*Neurology* 2008;70:e9-e13

DOI 10.1212/01.wnl.0000297515.86197.2e

**This information is current as of May 21, 2008**

### **Updated Information & Services**

including high resolution figures, can be found at:  
<http://n.neurology.org/content/70/3/e9.full>

### **References**

This article cites 9 articles, 1 of which you can access for free at:  
<http://n.neurology.org/content/70/3/e9.full#ref-list-1>

### **Permissions & Licensing**

Information about reproducing this article in parts (figures, tables) or in its entirety can be found online at:  
[http://www.neurology.org/about/about\\_the\\_journal#permissions](http://www.neurology.org/about/about_the_journal#permissions)

### **Reprints**

Information about ordering reprints can be found online:  
<http://n.neurology.org/subscribers/advertise>

*Neurology*® is the official journal of the American Academy of Neurology. Published continuously since 1951, it is now a weekly with 48 issues per year. Copyright . All rights reserved. Print ISSN: 0028-3878. Online ISSN: 1526-632X.

