

# Pearls and Oy-sters: Reversible iatrogenic Balint syndrome



Nicte I. Mejia MD\*  
Soojin Park, MD\*  
MingMing Ning, MD  
Ferdinando S.  
Buonanno, MD

Address correspondence and  
reprint requests to Dr.  
Ferdinando S. Buonanno,  
Massachusetts General  
Hospital, Boston, MA 02114  
fbuonanno@partners.org

The syndrome of ocular apraxia, simultagnosia, and optic ataxia originally described by Balint in 1909 is classically associated with bilateral parieto-occipital lesions, but can occur with other combinations of bihemispheric lesions.<sup>1,2</sup> This syndrome reflects multiple etiologies, most commonly vascular disease, but rarely improves rapidly.<sup>3</sup> We describe a patient with cerebral ischemia who developed Balint syndrome transiently in the setting of acute hypotension after nitroglycerin use; his presentation exemplifies the importance of blood pressure autoregulation in cerebral ischemia, and elucidates alternative etiologies of clinical-radiologic mismatch.

**CASE REPORT** A 60-year-old ambidextrous man with uncontrolled hypertension, hyperlipidemia, coronary artery disease, prior myocardial infarction, and a TIA developed difficulty remembering placement of items on a shelf. This was followed by difficulties with word-finding and comprehension, severe headache, and nausea. Upon initial evaluation at another hospital, he had persistent problems finding words and answering questions, and a blood pressure (BP) of 215/80 mm Hg but without other apparent neurologic deficits; cranial noncontrast computerized tomography (CT) was unremarkable. He was transferred to our institution, where his BP was 210/85 mm Hg and he showed hesitation and circumlocution of speech with semantic and phonemic paraphasic errors, as well as difficulties with naming, concentration, recall, calculation, and executing complex commands; he had slight trouble performing rapid alternating and fine motor movements with his left hand, and decreased sensation to all modalities in his left arm. Otherwise, he had no deficits in alertness, orientation, word repetition, cranial nerve testing, strength, reflexes, sensation, or gait. Brain MRI with gadolinium, including MR arteriography, demonstrated a diffusion-weighted image (DWI)

bright (figure, A) and apparent diffusion coefficient (ADC) dark lesion in his left posterior temporal area, evidence of plaque in the distal right common carotid artery, moderate narrowing of the proximal internal carotid artery, and a severe stenosis at the origin of the right vertebral artery (figure, B). He was treated with aspirin; blood pressure was controlled with labetalol. Six hours later, his systolic BP increased from 140 to 170 mm Hg over the course of a few minutes, and he had severe substernal crushing pain radiating to his left arm, for which he received a dose of nitroglycerin 0.4 mg sublingually. The BP acutely decreased to 90/62 mm Hg. Re-examination at this time revealed simultagnosia, optic ataxia, optic apraxia, flattening of the right nasolabial fold, and extinction to double simultaneous stimuli on his right side. Repeat brain MR imaging revealed a stable left posterior temporal infarct, and new small areas of restricted diffusion in both occipital lobes and left thalamus; there was a subtle increase in mean transit time suggesting perfusion-diffusion mismatch (figure, C). Concerns for possible basilar thrombosis led to CT angiography, which revealed posterior cerebral artery stenosis (figure, D). The patient's systolic BP returned to approximately 150 mm Hg over 2 hours, and visual symptoms resolved. He received IV heparin, and days later successfully underwent left vertebral angioplasty and stenting.

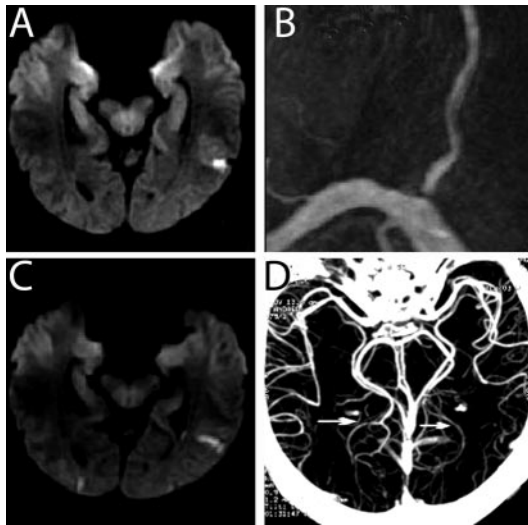
**DISCUSSION** Transient neurologic deficits can occur in patients with cerebral ischemia and hypertension as BP is acutely decreased. For example, the literature includes a report of a patient with pre-eclamptic posterior reversible encephalopathy syndrome who developed amaurosis after nitroglycerin-induced BP decrease.<sup>4</sup> There is also a description of a patient who underwent renal angioplasty and presented with reversible Balint syndrome with evidence of contrast penetration in both parieto-occipital cortices, suggesting that

\*These authors contributed equally.

From the Department of Neurology, Massachusetts General Hospital, Boston.

*Disclosure:* The authors report no disclosures.

**Figure** Imaging findings in patient with reversible iatrogenic Balint syndrome



(A) Diffusion-weighted MRI showing left posterior temporal hyperintensity consistent with acute ischemia; (B) MR angiogram showing proximal right vertebral artery stenosis; (C) follow-up diffusion-weighted MRI showing new ischemic lesions in bilateral occipital lobes; and (D) CT angiogram showing bilateral distal posterior cerebral artery stenosis (arrows).

disruption of the blood–brain barrier may lead to transient neurologic syndromes.<sup>5</sup> Our patient developed a reversible Balint syndrome after acute hypotension following nitroglycerin administration. Although the inability to perceive several items of a visual scene at a time (simultagnosia), shift gaze voluntarily to objects of interest despite unrestricted eye movements (ocular apraxia), and reach objects under visual guidance despite normal limb strength (optic ataxia) is usually said to occur as a manifestation of biparietal syndromes, it may be seen in other combinations of lesions, such as involvement of the left lateral geniculate body or optic radiation and the right parietal lobe, or even with bifrontal or pulvinar damage.<sup>1,6</sup>

Nitroglycerin, a vasodilator, decreases mean arterial pressure (MAP), and may alter global cerebral blood flow (CBF), reducing cerebral perfusion pressure (CPP).<sup>7</sup> In the setting of chronically underperfused parenchyma—as in this patient with preexisting vertebral artery stenosis—dysfunctional cerebrovascular autoregulation would explain why focal CBF could not be adequately maintained during the iatrogenic drop in MAP. The co-occurrence of cardiac and cerebral

atherosclerosis has been well-documented.<sup>8,9</sup> Our patient was treated successfully with vertebral artery stenting. Although there are currently no data that vertebral artery stenting provides better long-term outcomes than medical therapy (anti-coagulation or antiplatelet agents), it is a technically feasible procedure that offers an alternative to more technically challenging vertebral artery endarterectomies.<sup>10,11</sup> This case highlights the possibility of coexistent intracranial stenoses and cerebral dysautoregulation in patients with coronary disease and the need for caution when administering nitroglycerin to such patients.

## REFERENCES

1. Hecaen H, de Ajuriaguerra J. Balint's syndrome (psychic paralysis of visual fixation) and its minor forms. *Brain* 1954;77:373–400.
2. Rizzo M, Vecera SP. Psychoanatomical substrates of Balint's syndrome. *J Neurol Neurosurg Psychiatry* 2002;72:162–178.
3. Moreaud O. Balint syndrome. *Arch Neurol* 2003;60:1329–1331.
4. Finisterer J, Schlager T, Kopsa W, Wild E. Nitroglycerin-aggravated pre-eclamptic posterior reversible encephalopathy syndrome (PRES). *Neurology* 2003;61:715–716.
5. Merchut MP, Richie B. Transient visuospatial disorder from angiographic contrast. *Arch Neurol* 2002;59:851–854.
6. Valenza N, Murray MM, Ptak R, Vuilleumier P. The space of senses: impaired crossmodal interactions in a patient with Balint syndrome after bilateral parietal damage. *Neuropsychologia* 2004;42:1737–1748.
7. Weyland A, Grune F, Buhre W, Kazmaier S, Stephan H, Sonntag H. [The effect of nitroglycerin on cerebrovascular circulation, cerebrovascular CO<sub>2</sub>-reactivity and blood flow rate in basal cerebral arteries]. *Anaesthesist* 1996;45:1037–1044.
8. Uehara T, Tabuchi M, Mori E. Risk factors for occlusive lesions of intracranial arteries in stroke-free Japanese. *Eur J Neurol* 2005;12:218–222.
9. Gongora-Rivera F, Labreuche J, Jaramillo A, Steg PG, Hauw JJ, Amarenco P. Autopsy prevalence of coronary atherosclerosis in patients with fatal stroke. *Stroke Epub* 2007 Mar 1.
10. Coward LJ, McCabe DJH, Ederle J, Featherstone RL, Clifton A, Brown MM. Long-term outcome after angioplasty and stenting for symptomatic vertebral artery stenosis compared with medical treatment in the carotid and vertebral artery transluminal angioplasty study (CAVATAS). *Stroke* 2007;38:1526–1530.
11. Cloud GC, Crawley F, Clifton A, McCabe DJH, Brown MM, Markus HS. *J Neurol Neurosurg Psychiatry* 2003;74:586–590.

# Neurology<sup>®</sup>

## **Pearls and Oysters: Reversible iatrogenic Balint syndrome**

Nicte I. Mejia, Soojin Park, MingMing Ning, et al.

*Neurology* 2008;70:e97-e98

DOI 10.1212/01.wnl.0000314730.64232.5a

**This information is current as of June 9, 2008**

<b>Updated Information &amp; Services</b>	including high resolution figures, can be found at: <a href="http://n.neurology.org/content/70/24/e97.full">http://n.neurology.org/content/70/24/e97.full</a>
<b>Supplementary Material</b>	Supplementary material can be found at: <a href="http://n.neurology.org/content/suppl/2008/11/16/70.24.e97.DC1">http://n.neurology.org/content/suppl/2008/11/16/70.24.e97.DC1</a>
<b>References</b>	This article cites 10 articles, 4 of which you can access for free at: <a href="http://n.neurology.org/content/70/24/e97.full#ref-list-1">http://n.neurology.org/content/70/24/e97.full#ref-list-1</a>
<b>Citations</b>	This article has been cited by 1 HighWire-hosted articles: <a href="http://n.neurology.org/content/70/24/e97.full##otherarticles">http://n.neurology.org/content/70/24/e97.full##otherarticles</a>
<b>Permissions &amp; Licensing</b>	Information about reproducing this article in parts (figures, tables) or in its entirety can be found online at: <a href="http://www.neurology.org/about/about_the_journal#permissions">http://www.neurology.org/about/about_the_journal#permissions</a>
<b>Reprints</b>	Information about ordering reprints can be found online: <a href="http://n.neurology.org/subscribers/advertise">http://n.neurology.org/subscribers/advertise</a>

*Neurology*® is the official journal of the American Academy of Neurology. Published continuously since 1951, it is now a weekly with 48 issues per year. Copyright . All rights reserved. Print ISSN: 0028-3878. Online ISSN: 1526-632X.

