

# Teaching *NeuroImage*: Traumatic internuclear ophthalmoplegia

Jefferson T. Miley,  
MD  
Gustavo J. Rodriguez,  
MD  
Eric M. Hernandez,  
MD, PhD  
Scott R. Bundlie, MD

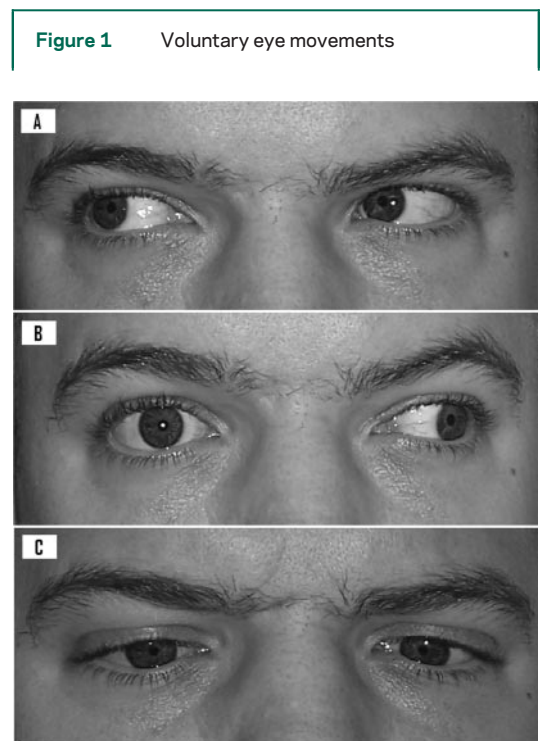
Address correspondence and  
reprint requests to Dr. Jefferson  
T. Miley, University of  
Minnesota Medical School, 420  
Delaware Street SE, MMC 295,  
12-100 PWB, Minneapolis, MN  
55455  
miley011@umn.edu

A 26-year-old right-handed man presented to the emergency department with a scalp laceration following a fall while walking on an icy sidewalk. He was intoxicated at the time and was witnessed by a friend to lose his footing, falling backward. There was brief loss of consciousness, lasting less than a minute. The patient himself had amnesia for the fall and for his transportation by ambulance. In the emergency department he had a headache, nausea, and “fuzzy” vision when looking to the left. The patient admitted to use of alcohol earlier that day but denied the use of any other drug.

Upon physical examination, there was a 7-cm scalp laceration over his right occiput. Neurologic examination was unremarkable, except for abnormal eye movements. Vertical eye movements were conjugate. With gaze to the left, there was no adduction of the right eye and the abducting left eye demonstrated outbeating nystagmus. However, with convergence maneuvers, both eyes demonstrated normal adduction (figure 1). There was no ptosis, and pupils were symmetric with normal reaction to light. Head tilt was not present, and there were no other findings.

CT of the head was unrevealing. MRI of the brain was performed 4 hours after injury and revealed a small focus of hemorrhage at the pontomesencephalic junction (figure 2). Within 1 week, the patient’s diplopia fully resolved. However, further evaluation including repeat neuroimaging was not obtained because the patient was lost to follow-up.

Internuclear ophthalmoplegia (INO) is a sign with precise localizing value. Cortical input for horizontal eye movement reaches the sixth nerve nucleus via the paramedian pontine reticular formation. The sixth nerve nucleus contains motor neurons that innervate the ipsilateral lateral rectus and interneurons that cross the midline and form the contralateral medial longitudinal fascic-



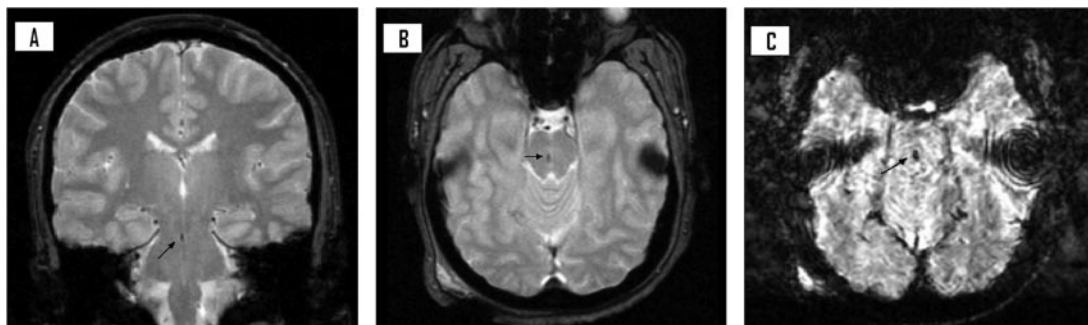
(A) Right gaze. (B) Left gaze. (C) Convergence. See text for details.

ulus (MLF). Interneurons from the MLF synapse with motor neurons in the contralateral oculomotor nucleus, which innervate the contralateral medial rectus.<sup>1</sup> INO arises from a lesion of the MLF. The essential clinical finding is weakness of adduction of the ipsilateral eye, although skew deviation and nystagmus may also accompany.

INO is a classic finding in multiple sclerosis and may also be seen with brainstem stroke, rarely as an isolated finding.<sup>2</sup> Few cases of traumatic INO have been previously reported, and again rarely as a solitary deficit.<sup>3-10</sup> Neuroimaging may reveal a normal brainstem,<sup>5</sup> although in a few cases CT of the head revealed hemorrhage,<sup>3,7</sup> and in most cases MRI was required to demonstrate the lesion.<sup>3,4,7,9,10</sup> Prognosis is usually good, and, as in our case, most traumatic INO resolves.<sup>3,4,7-10</sup>

From the Department of Neurology, University of Minnesota, Minneapolis.  
*Disclosure:* The authors report no conflicts of interest.

**Figure 2** MRI of the brain showing a pontomesencephalic hemorrhage (arrows)



(A) Coronal gradient echo. (B) Axial gradient echo. (C) Axial susceptibility MRI.

## REFERENCES

1. Kandel ER, Schwartz JH, Jessell TM. Principles of neural science, 3rd edition. New York: Elsevier; 1991.
2. Kim JS. Internuclear ophthalmoplegia as an isolated or predominant symptom of brainstem infarction. *Neurology* 2004;62:1491–1496.
3. Walsh WP, Hafner JW, Kattah JC. Bilateral internuclear ophthalmoplegia following minor head trauma. *J Emerg Med* 2003;24:19–22.
4. Chan JW. Isolated unilateral post-traumatic internuclear ophthalmoplegia. *J Neuroophthalmol* 2001;21:212–213.
5. Constantoyannis C, Tzortzidis F, Papadakis N. Internuclear ophthalmoplegia following minor head injury: a case report. *Br J Neurosurg* 1998;12:377–379.
6. Keane JR. Internuclear ophthalmoplegia: unusual causes in 114 of 410 patients. *Arch Neurol* 2005;62:714–717.
7. Strauss C, Ganslandt O, Huk WJ, et al. Isolated unilateral internuclear ophthalmoplegia following head injury: findings in magnetic resonance imaging. *Neuroophthalmology* 1995;15:15–19.
8. Baker RS. Internuclear ophthalmoplegia following head injury: a case report. *J Neurosurg* 1979;51:552–555.
9. Hsu HC, Chen HJ, Lu K, Liang CL. Reversible bilateral internuclear ophthalmoplegia following head injury. *Acta Ophthalmol Scand* 2001;79:57–59.
10. Jung DS, Park K-P. Posttraumatic bilateral internuclear ophthalmoplegia with exotropia. *Arch Neurol* 2005;61:429.

# Neurology<sup>®</sup>

## Teaching *NeuroImage*: Traumatic internuclear ophthalmoplegia

Jefferson T. Miley, Gustavo J. Rodriguez, Eric M. Hernandez, et al.

*Neurology* 2008;70:e3-e4

DOI 10.1212/01.wnl.0000280462.85951.3c

**This information is current as of May 21, 2008**

<b>Updated Information &amp; Services</b>	including high resolution figures, can be found at: <a href="http://n.neurology.org/content/70/1/e3.full">http://n.neurology.org/content/70/1/e3.full</a>
<b>References</b>	This article cites 9 articles, 1 of which you can access for free at: <a href="http://n.neurology.org/content/70/1/e3.full#ref-list-1">http://n.neurology.org/content/70/1/e3.full#ref-list-1</a>
<b>Subspecialty Collections</b>	This article, along with others on similar topics, appears in the following collection(s): <b>Brain trauma</b> <a href="http://n.neurology.org/cgi/collection/brain_trauma">http://n.neurology.org/cgi/collection/brain_trauma</a> <b>Intracerebral hemorrhage</b> <a href="http://n.neurology.org/cgi/collection/intracerebral_hemorrhage">http://n.neurology.org/cgi/collection/intracerebral_hemorrhage</a> <b>MRI</b> <a href="http://n.neurology.org/cgi/collection/mri">http://n.neurology.org/cgi/collection/mri</a> <b>Ocular motility</b> <a href="http://n.neurology.org/cgi/collection/ocular_motility">http://n.neurology.org/cgi/collection/ocular_motility</a>
<b>Permissions &amp; Licensing</b>	Information about reproducing this article in parts (figures, tables) or in its entirety can be found online at: <a href="http://www.neurology.org/about/about_the_journal#permissions">http://www.neurology.org/about/about_the_journal#permissions</a>
<b>Reprints</b>	Information about ordering reprints can be found online: <a href="http://n.neurology.org/subscribers/advertise">http://n.neurology.org/subscribers/advertise</a>

*Neurology*® is the official journal of the American Academy of Neurology. Published continuously since 1951, it is now a weekly with 48 issues per year. Copyright . All rights reserved. Print ISSN: 0028-3878. Online ISSN: 1526-632X.

