

Teaching *NeuroImage*: When right atrial myxoma meets patent foramen ovale

A case of paradoxical brain embolism

M. Tondelli, MD
J. Mandrioli, MD
G. Ficarra, MD
R. Pentore, MD
F. Girolami, MD
I. Ghidoni, MD
V. Agnoletto, MD

Address correspondence and
reprint requests to Dr. J.
Mandrioli, Clinica
Neurologica, Dipartimento di
Neuroscienze, Nuovo Ospedale
Civile S. Agostino Estense, Via
Giardini 1355, 41100 Modena,
Italy
jessicamandrioli@libero.it

A previously healthy 49-year-old woman was admitted with dysarthria, right facio-brachial paresis, and hypesthesia. Brain CT and MRI showed left frontal opercular infarction (figure 1A). Transcranial color-coded duplex sonography did not detect vessel abnormalities but revealed right-to-left shunt (RLSh) (figure 1B). Transesophageal echocardiogram (figure 1C) identified a patent foramen ovale (PFO) (arrow) and a right atrial myxoma (arrowheads). Coronary angiography showed that the distal circumflex artery supplied the myxoma (figure 1D). Myxoma resection (figure 2) and PFO closure were performed surgically in one operation without complications.

Cardiac myxoma is an uncommon cause of stroke (0.4%). Only 15% to 20% of myxomas are detected in the right atrium.^{1,2} In these cases, RLSh is required for neurologic symptoms to occur. Our case report represents a rare cause of paradoxical brain embolism.

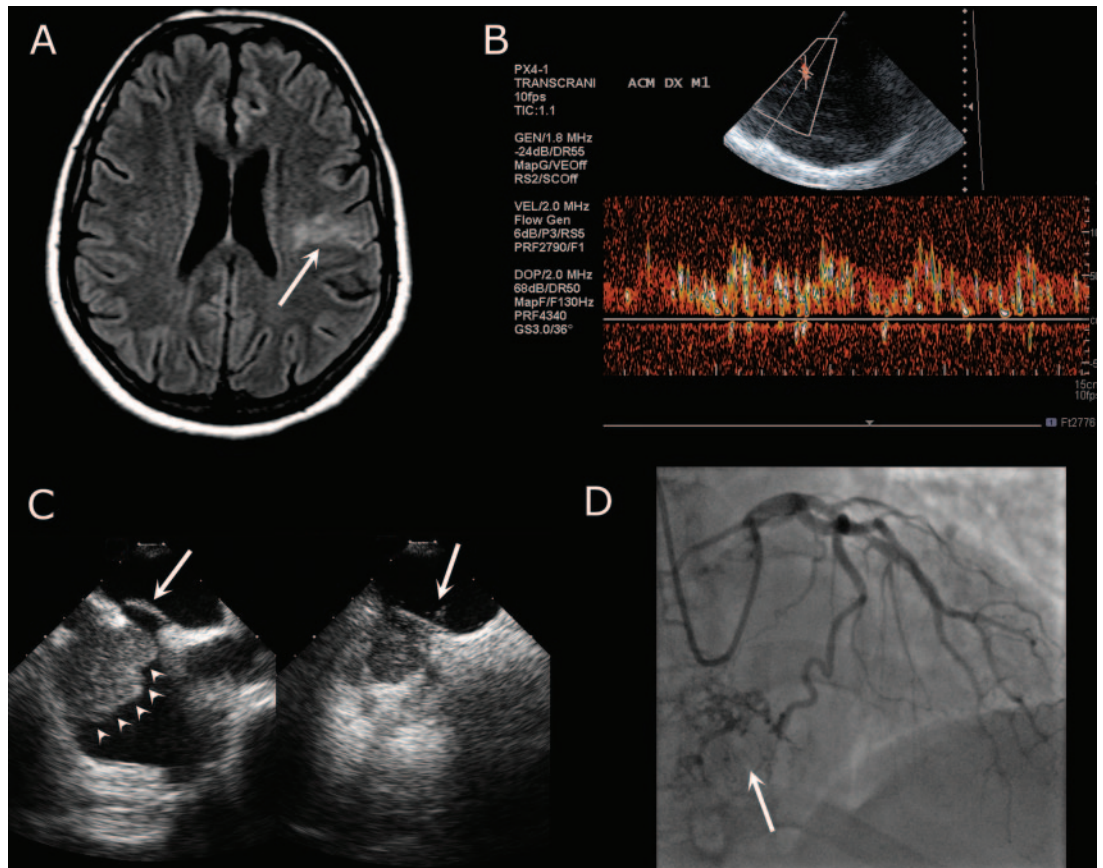
REFERENCES

1. Reynen K. Cardiac myxomas. *N Engl J Med* 1995;333:1610–1617.
2. Elkindi EI, Donnan GA. Neurological manifestations of cardiac myxoma: a review of the literature and report of cases. *Intern Med J* 2004;34:243–249.

From the Neurology Clinic (M.T., J.M., R.P., F.G.), Department of Neuroscience, and Department of Pathologic Anatomy and Legal Medicine (G.F.), Section of Pathologic Anatomy, University of Modena and Reggio Emilia, Modena, Italy; Divisions of Cardiovascular Surgery (I.G.), Hesperia Hospital, Modena; and Cardiology Division (V.A.), St. Agostino-Estense Hospital, Modena.

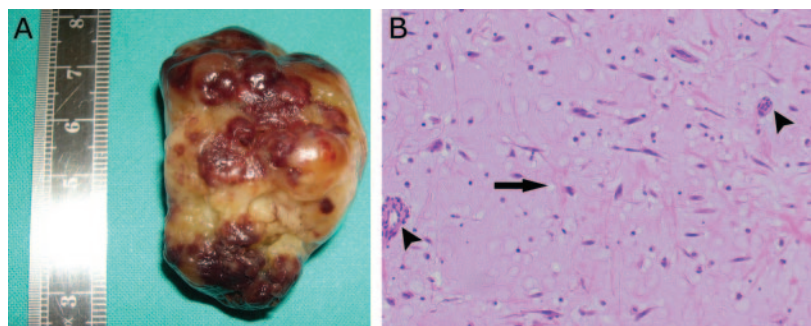
Disclosure: The authors report no conflicts of interest.

Figure 1 Preoperative evaluation findings



(A) Axial FLAIR T2-weighted MRI: left frontal opercular infarction (arrow). (B) Transcranial color-coded duplex sonography: right-to-left shunt (RLSh) with shower of bubbles (>25 high intensity transient signals). (C) Transesophageal echocardiography: patent foramen ovale (PFO) (arrow) and myxoma (4.2 × 2.4 cm) (arrowheads) protruding on RLSh. (D) Coronary angiography showing myxoma supplied by distal circumflex artery.

Figure 2 Postoperative findings after myxoma resection



(A) Macroscopic image of myxoma, showing highly irregular, multilobulated appearance. (B) Histologic slide of the myxoma, showing stellate cells (arrow), vascular structures (arrowheads), and myxoid ground substance (hematoxylin-eosin stain).

Neurology[®]

Teaching *NeuroImage*: When right atrial myxoma meets patent foramen ovale: A case of paradoxical brain embolism

M. Tondelli, J. Mandrioli, G. Ficarra, et al.

Neurology 2008;70:e1-e2

DOI 10.1212/01.wnl.0000298943.86359.e7

This information is current as of May 21, 2008

Updated Information & Services

including high resolution figures, can be found at:
<http://n.neurology.org/content/70/1/e1.full>

References

This article cites 2 articles, 0 of which you can access for free at:
<http://n.neurology.org/content/70/1/e1.full#ref-list-1>

Permissions & Licensing

Information about reproducing this article in parts (figures, tables) or in its entirety can be found online at:
http://www.neurology.org/about/about_the_journal#permissions

Reprints

Information about ordering reprints can be found online:
<http://n.neurology.org/subscribers/advertise>

Neurology® is the official journal of the American Academy of Neurology. Published continuously since 1951, it is now a weekly with 48 issues per year. Copyright . All rights reserved. Print ISSN: 0028-3878. Online ISSN: 1526-632X.

