

Practice parameter: Diagnostic assessment of pediatric status epilepticus

In this evidence-based AAN review, Riviello et al. considered the diagnostic utility of electrolytes, blood cultures, lumbar puncture, antiepileptic drug levels, toxicology, metabolic studies, EEG, and neuroimaging in 1,859 children and etiology in 2,093 children. Most recommendations are at level C (possibly supported) or U (data inadequate) and prospective studies are needed.

see page 1542

Neurologic involvement in Rosai-Dorfman disease

Kidd et al. present two cases of Rosai-Dorfman disease with neurologic involvement. This disorder is characterized by histiocytic infiltration of lymphoid tissue and other organs.

see page 1551

Lifetime lead dose and cognitive function

Shih et al. studied the association of lifetime lead dose, measured as current lead concentrations in tibia bone, with cognitive function in 991 community-dwelling urban adults. Tibia lead levels were associated with decreased performance in all seven cognitive domains assessed. Some of what has been termed normal age-related decline in cognitive function may be due to ubiquitous neurotoxicants such as lead.

see page 1556

The editorial by Weisskopf and Myers notes that the Shih et al. findings are consistent with results from the Normative Aging Study, indicating a significant association between higher bone lead concentrations and worse decline over time on visuomotor/visuospatial tests. Cumulative exposure to even low levels of lead—levels to which most of us might be exposed in our lives—may have adverse neurologic effects. These studies suggest that we can no longer rely on current blood lead as an exposure measure. However, more work is needed to establish that subtle cognitive decline is indeed the result of cumulative exposure to lead.

see page 1536

POLG1 mutations and PD

Parkinsonism has been noted in families with autosomal progressive external ophthalmoplegia caused by *POLG1* mutations. Tiangyou et al. report that *POLG1* mutations are a rare cause of PD in the general population.

see page 1698

Erythermalgia: A sodium channelopathy

Inherited erythermalgia, characterized by burning pain in response to mild warmth, is caused by mutations in the Nav1.7 sodium channel. This channel is selectively expressed in sympathetic ganglion and dorsal root ganglion neurons including thermal nociceptors. Choi et al. now describe an erythermalgia mutation within the Nav1.7 voltage sensor.

see page 1563

The editorial by Schorge and Páček notes that inherited erythermalgia is an episodic disorder and like many other episodic neurologic disorders, patients often function normally in between attacks. In the case of inherited erythermalgia, the symptoms include intense peripheral burning pain, often activated by heat or exercise. The importance of Nav1.7 in the transmission of pain was first made clear almost simultaneously by genetic association with inherited erythermalgia and by a mouse knockout. There are now seven mutations linked to inherited erythermalgia and so far their functional characterization suggests that increasing the activity of Nav1.7 specifically increases the activity of DRG neurons leading to the increased sensation of pain. The change studied by Choi et al. does not affect any of the well-studied charged residues in the S4 transmembrane segment. This change has dramatic consequences on the gating of the channel: it opens earlier, shuts later, and generally responds more to smaller stimuli. The heat-triggered episodes of burning pain that characterize inherited erythermalgia (SCN9A) parallel heat effects on other sodium channel mutations.

see page 1538

Effect of motor cortex TMS on chronic neuropathic pain

Lefaucheur et al. found that GABAergic inhibitory processes were defective within the motor cortex corresponding to the painful hand of patients with chronic neuropathic pain. Intracortical inhibition was restored after transcranial magnetic stimulation of the motor cortex. This effect correlated with pain relief.

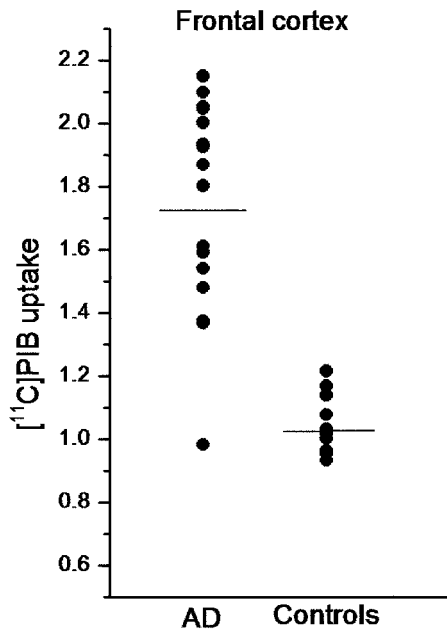
see page 1568

Vascular risk factors and cognitive decline in male twins

Xiong et al. found that among older male twin pairs discordant for diabetes the diabetic showed greater cognitive decline than the non-diabetic co-twin. Twin pairs discordant for hypertension, elevated body mass index, or hypercholesterolemia did not show differences in cognitive decline within twin pairs.

see page 1586

In vivo assessment of amyloid accumulation in patients with AD



Kemppainen et al. compared the uptake of an amyloid-binding PET ligand, [¹¹C] PIB, in patients with AD vs healthy controls. Voxel-based analysis covering the whole brain revealed widespread distribution of increased uptake in patients with AD. The most prominent increase vs controls was seen in the frontal cortex.

see page 1575

Creatine deficiency in mental retardation

Lion-François et al. found creatine deficiency syndromes in 2.7% of 188 children in their referral population: Five of 114 boys and none of 74 girls.

see page 1713

Peritumoral infarction after surgery for brain tumors

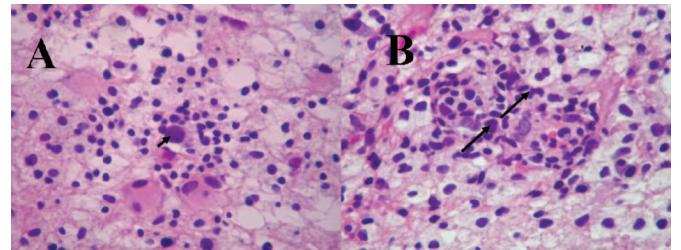
Ulmer et al. found that peritumoral infarction after surgery for glioblastoma is common and may explain some new postoperative deficits. Enhancement of peritumoral infarcts can be misinterpreted as tumor progression.

see page 1668

The editorial by Wick and Kaufmann notes that the study by Ulmer et al. raises two important points. It adds a new caveat to the conclusions drawn from early MRI changes in patients with glioblastoma. Second, the study points to the importance of postoperative MRI within 72 hours following resection of brain tumors to measure the extent of tumor resection prior to the occurrence of expected postoperative changes. DWI should be included in study protocols whenever feasible.

see page 1540

Treatment of the immune reconstitution inflammatory syndrome in AIDS



(A) "Ground glass" viral inclusion in oligodendrocyte with inflammatory cells (arrow). HE 400 \times . (B) Inflammatory cells around vessel wall and within the brain parenchyma (arrows). HE 400 \times .

Martinez et al. report a patient with AIDS who developed an immune reconstitution inflammatory syndrome (IRIS) associated with progressive multifocal leukoencephalopathy. The patient improved with corticosteroids and temporary interruption of antiretroviral agents.

see page 1692

Neurology®

November 14 Highlights
Neurology 2006;67;1534-1535
DOI 10.1212/01.wnl.0000248398.88172.68

This information is current as of November 13, 2006

Updated Information & Services

including high resolution figures, can be found at:
<http://n.neurology.org/content/67/9/1534.full>

Permissions & Licensing

Information about reproducing this article in parts (figures, tables) or in its entirety can be found online at:
http://www.neurology.org/about/about_the_journal#permissions

Reprints

Information about ordering reprints can be found online:
<http://n.neurology.org/subscribers/advertise>

Neurology® is the official journal of the American Academy of Neurology. Published continuously since 1951, it is now a weekly with 48 issues per year. Copyright . All rights reserved. Print ISSN: 0028-3878. Online ISSN: 1526-632X.

