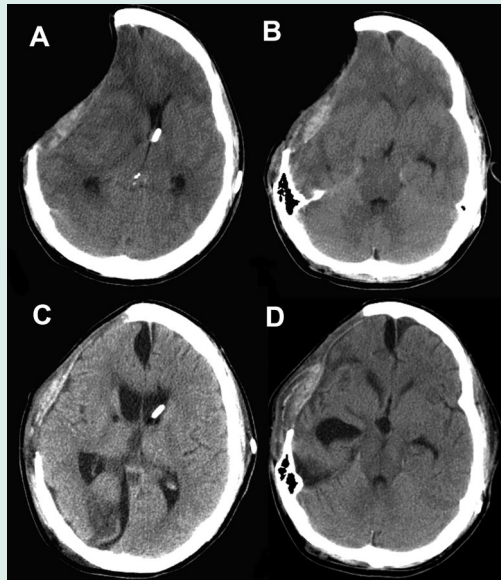


**Paradoxical herniation caused by hemicraniectomy**



*CT scan showing midline shift with subfalcine herniation in the direction opposite the site of craniectomy (A) and midbrain compression with effacement of the quadrigeminal cistern (B). Repeat CT scan after clamping of the VP shunt, Trendelenburg positioning, and hypervolemic therapy. Resolution of midline shift and subfalcine herniation (C) and improvement in the effacement of the basal cisterns (D).*

Fields et al. report a patient with a cerebral contusion and a subdural hematoma who developed midline shift away from the site of hemicraniectomy—“paradoxical herniation.” This potentially life-threatening but treatable condition presents with progressive neurologic deterioration and a sunken skull defect.

**see page 1513**

**Cerebral herniation months after decompressive craniotomy: How can this be?**

Commentary by Galen Henderson, MD

Fields et al. report a case of a 24-year-old man who suffered head trauma and a temporal contusion and was treated with the evacuation of the subdural hematoma, anterior temporal lobectomy, hemicraniectomy, and ventriculoperitoneal shunt. Two months after the surgical procedure and before the reconstructive cranioplasty, the patient underwent a lumbar puncture as part of fever workup and within days of the procedure became comatose from cerebral herniation documented by a cerebral imaging study.

Hemicraniectomy prevents cerebral herniation and death in patients who have deteriorated neurologically from brain tissue shifts caused by cerebral edema from ischemic strokes or other

space-occupying lesions. The patients most likely to benefit from the procedure are young.<sup>1</sup> Ventriculoperitoneal shunts have been used for decades to treat communicating or noncommunicating hydrocephalus by providing an alternative route for CSF egress when intracranial pressure rises above a certain set point. With either procedure there are potential complications that can be anticipated.

Despite an unrepaired decompressive procedure and ventriculoperitoneal shunt, patients can herniate from a CSF leak or a negative pressure process. Cerebral herniation most commonly occurs with increased intracranial pressure rather than a low or negative pressure process. This case illustrates the

importance of recognizing the pathophysiologic process that is occurring and withholding the usual treatments for herniation: hyperosmolar therapy, hyperventilation, head-of-bed elevation. These measures may hasten death. This case adds support to the concept that brain tissue shifts are responsible for the decreased level of consciousness rather than the absolute increase in intracranial pressure measurement.<sup>2</sup>

**References**

1. Gupta R, Connolly ES, Mayer S, Elkind MS. Hemicraniectomy for massive middle cerebral artery territory infarction: a systematic review. *Stroke* 2004;35:539–543.
2. Ropper A. Lateral displacement of the brain and level of consciousness in patients with an acute hemispherical mass. *N Engl J Med* 1986;314:953–958.

**see page 1513**

# Neurology<sup>®</sup>

**October 24 Highlight and Commentary: Cerebral herniation months after decompressive craniotomy: How can this be?**

*Neurology* 2006;67;1323

DOI 10.1212/01.wnl.0000246081.04287.50

**This information is current as of October 23, 2006**

<b>Updated Information &amp; Services</b>	including high resolution figures, can be found at: <a href="http://n.neurology.org/content/67/8/1323.full">http://n.neurology.org/content/67/8/1323.full</a>
<b>References</b>	This article cites 2 articles, 1 of which you can access for free at: <a href="http://n.neurology.org/content/67/8/1323.full#ref-list-1">http://n.neurology.org/content/67/8/1323.full#ref-list-1</a>
<b>Permissions &amp; Licensing</b>	Information about reproducing this article in parts (figures, tables) or in its entirety can be found online at: <a href="http://www.neurology.org/about/about_the_journal#permissions">http://www.neurology.org/about/about_the_journal#permissions</a>
<b>Reprints</b>	Information about ordering reprints can be found online: <a href="http://n.neurology.org/subscribers/advertise">http://n.neurology.org/subscribers/advertise</a>

*Neurology*® is the official journal of the American Academy of Neurology. Published continuously since 1951, it is now a weekly with 48 issues per year. Copyright . All rights reserved. Print ISSN: 0028-3878. Online ISSN: 1526-632X.

