

# Periventricular heterotopia in fragile X syndrome

**Abstract**—The authors describe two unrelated individuals with fragile X syndrome (FXS) due to marked expansion and instability of the CGG trinucleotide repeats within the fragile X mental retardation 1 gene (*FMR1*) and periventricular heterotopia (PH). This observation suggests that the *FMR1* gene is involved in neuronal migration and that abnormal neuronal migration, even beyond the resolution of MRI, contributes to the neurologic phenotype of FXS.

NEUROLOGY 2006;67:713–715

F. Moro, PhD\*; T. Pisano, MD\*; B. Dalla Bernardina, MD; R. Polli, PhD; A. Murgia, MD, PhD; L. Zoccante, MD; F. Darra, MD; A. Battaglia, MD; T. Pramparo, PhD; O. Zuffardi, PhD; and R. Guerrini, MD

Fragile X syndrome (FXS) (OMIM 309550), the most common inherited form of mental retardation, is characterized by cognitive impairment, attention-deficit/hyperactivity disorder, autistic behavior, seizures, and additional clinical manifestations that involve other organs than the brain.<sup>1</sup> FXS is caused by mutations of the fragile X mental retardation 1 (*FMR1*) gene (Xq27.3). The mutation is usually represented by the abnormal expansion of the CGG triplet repeats located in the 5' untranslated region of the gene, with hypermethylation of the promoter and repeated sequences. These so-called FRAXA full mutations cause transcriptional silencing and ultimately lead to deficit of the gene product, the fragile X mental retardation protein (FMRP).<sup>1</sup>

Periventricular heterotopia (PH) is a neuronal migration disorder consisting of nodules of gray matter located along the lateral ventricles. Classic PH with bilateral contiguous and symmetric nodules has been associated with mutations of the *FLNA* gene (Xq28) (OMIM 300049).<sup>2</sup> A rare recessive form of bilateral PH with severe mental retardation has been reported owing to mutations of the *ARFGEF2* gene.<sup>3</sup> Some patients with PH associated with chromosomal abnormalities of the distal portion 5p have been described, suggesting an additional distinctive syndrome.<sup>3</sup> However, in most cases of PH, no mutations of known genes are found.<sup>3</sup> Considering the pheno-

typic diversity of PH, wide genetic heterogeneity can be hypothesized.

Here, we describe two patients with PH and typical FXS. This association expands the spectrum of phenotypes featuring PH and suggests that the *FMR1* product (FMRP) may be involved in neuronal migration.

**Methods.** We studied two unrelated individuals using clinical information, brain MRI, EEGs, and cognitive testing. DNA was extracted from peripheral blood leukocytes. Southern blot was performed: DNA was subjected to double digestion with EcoRI/EagI and electrophoresed on agarose gel. Blotting was performed with Hybond N+ membrane (Amersham Bioscience); the hybridization probe StB12.3<sup>4</sup> was radioactively labeled by the Random Primers DNA Labeling System (Invitrogen). Autoradiography was performed for 1 to 4 days. PCR of *FMR1* CGG repeats was performed with GC-Rich System (Roche) and primers *c* (6-FAM 5'-GCTCAGCTCCGTTTCGGTTTCACTTCCGGT-3') and *f* (5'-AGCCCCGCACTTCCACCAGCTCCTCCA-3') according to the manufacturer. The amplicons were sequenced (ABI Prism 310) and the size of alleles determined by the GENESCAN software (Applied).

High-resolution karyotyping (>550 bands) was performed in proband 2. Molecular karyotyping was performed in both probands through array CGH with the Agilent kit. This platform is a 60-mer oligonucleotide-based microarray that allows genome-wide survey and molecular profiling of genomic aberrations with 75-kb resolution. DNA of patients and a male control was double digested with RsaI and AluI (Promega). Each digested DNA was purified and labeled by random priming (Invitrogen) using Cy5-dUTP for the patients and Cy3-dUTP for control DNA. Hybridization was performed after probes denaturation and pre-annealing with Cot-1 DNA. After two washing steps, the array was analyzed with the Agilent scanner and the Feature Extraction software (version 8.0). A graphic overview was obtained using CGH analytics software (version 3.1).

*FLNA* coding regions were amplified by PCR, and the mutation screening was performed by Wave denaturing high-performance liquid chromatography (Transgenomic, La Jolla, CA).<sup>5</sup>

**Results.** Proband 1 is a 13-year-old boy with mental retardation and attention deficit disorder. At age 7 years, his IQ score was 40 (Wechsler Preschool and Primary Scale of Intelligence). Clinical examination revealed relative macrocephaly, large ears, prominent jaw, scoliosis, and macroorchidism. Interictal EEG showed spike activity in the right centroparietal region, but no seizures were reported. Brain MRI showed three heterotopic nodules beneath the frontal horn of the left lateral ventricle, the right trigon (figure, A) and the left occipital horn, as well as underrotated hippocampi (figure, C). Southern blot analysis revealed a condition of mosaicism with the presence of a

\*These authors contributed equally to this article.

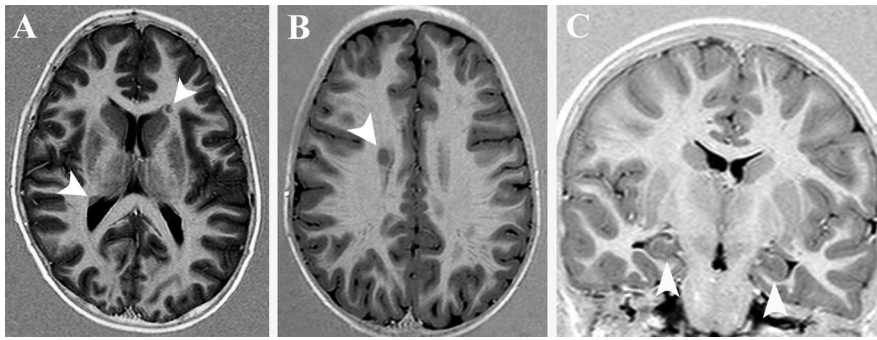
From the IRCCS Fondazione Stella Maris (F.M., T.P., A.B., R.G.), Pisa, Italy; Division of Child Neurology and Psychiatry (R.G.), University of Pisa, Pisa, Italy; Child Neuropsychiatry Unit (B.D.B., L.Z., F.D.), University of Verona, Verona, Italy; Department of Pediatrics (R.P., A.M.), University of Padua, Padua, Italy; Genetica Medica (T.P., O.Z.), Università di Pavia, Pavia, Italy; and IRCCS Policlinico San Matteo (O.Z.), Pavia, Italy.

Supported in part by grants from the Fondazione Mariani (grant R-04-35 to Drs. Moro, Pisano, and Guerrini) and the Telethon Foundation (grant GGP05177 to Drs. Pramparo, Zuffardi, and Guerrini).

Disclosure: The authors report no conflicts of interest.

Received December 23, 2005. Accepted in final form April 19, 2006.

Address correspondence and reprint requests to Dr. Renzo Guerrini, Division of Child Neurology and Psychiatry, University of Pisa and IRCCS Fondazione Stella Maris, via dei Giacinti 2, 56018 Calambrone Pisa, Italy; e-mail: renzo.guerrini@inpe.unipi.it



**Figure.** Brain MRI scans of Patients 1 and 2. Axial inversion recovery (IR) of Patients 1 and 2. (A) Two heterotopic nodules lay beneath the left frontal horn (arrowhead) and the right trigon (arrowhead), respectively. (B) A single nodule is located beneath the right lateral ventricle (arrowhead). (C) Coronal IR of Patient 1 showing underrotated hippocampi (arrowheads).

FRAXA full mutation characterized by a large and heterogeneous expansion ( $\Delta > 1.2$  kb) of hypermethylated CGG repeats and an additional unmethylated fragment of approximately 2.6 kb. This latter fragment was consistent with the size (198 bp) of the product obtained by PCR amplification with primers immediately flanking the repeat region. The sequence analysis showed this fragment to be the result of a deletion limited to the CGG triplets, likely to have occurred in the early embryo within the extremely unstable region of repeated sequences. Karyotype was normal after array CGH analysis. No mutations of *FLNA* were found.

Proband 2 is a 4.5-year-old boy. At age 6 months, he underwent surgery for congenital labioschisis. Cognitive testing at age 4 years (Griffiths Scale) showed an IQ of 54 with selective language impairment. Clinical examination revealed macrocephaly, large ears, and prominent jaw. Interictal EEG showed bilateral spike activity in the centroparietal regions, but no seizures were reported. Brain MRI showed a single heterotopic nodule beneath the right lateral ventricle (figure, B). Molecular analysis of *FMR1* showed a classic FRAXA full mutation with a heterogeneous expansion ( $\Delta > 1$  kb) of the CGG repeat fragments and complete hypermethylation of the region. High-resolution chromosome analysis and array CGH analysis were normal. No mutations of *FLNA* were found.

**Discussion.** The two patients described had typical FXS and PH, a previously unreported association. Brain abnormalities have been documented by MRI scan in patients with FXS, and these include decreased size of the cerebellar vermis and the superior temporal gyrus and increased volume of the hippocampus, amygdala, caudate nucleus, and thalamus.<sup>6</sup> Anatomic and histologic examinations of the brains of patients with FXS showed dendritic spine dysgenesis in the neocortex,<sup>7</sup> which was considered a nonspecific indicator of abnormally delayed dendritic development. Although gray matter heterotopia has not been previously observed, small clusters of neurons scattered throughout the subcortical white matter and a small olivary heterotopia below the inferior cerebellar peduncle were reported in two neuropathologic studies.<sup>8,9</sup> Our patients showed isolated or scattered periventricular heterotopic nodules, but diffuse neuronal heterotopia beyond the resolution of MRI is possible.

Structural brain abnormalities in FXS have been attributed to the lack of FMRP with consequent impairment of synaptogenesis during early brain development.<sup>6,10</sup> It is the transcriptional silencing of *FMR1*, in the FRAXA full mutation, that leads to FMRP deficiency, with consequent impairment of synaptic plasticity and, ultimately, of cognitive function.<sup>1</sup>

FMRP, whose function has not been completely elucidated, has been described as an RNA-binding protein that complexes with messenger ribonucleoproteins in the neuron's cytoplasm interacting with specific RNA transcripts and other proteins.

FMRP, as a translational suppressor, might also regulate local protein synthesis of specific RNAs in the dendrites in response to synaptic stimulation signals.<sup>1</sup> Recent studies about the role of mRNA ligands specifically regulated by FMRP identified several targets including microtubule-associated protein 1B and semaphorin 3F<sup>1</sup> that are involved in axon guidance and cell motility.

PH, most often bilateral and symmetric, has been observed in several syndromes. The main syndromes with PH include classic X-linked bilateral periventricular nodular heterotopia (BPNH) due to *FLNA* mutations,<sup>2</sup> and BPNH with frontonasal dysplasia, BPNH with syndactyly and severe mental retardation, which have been described predominantly in boys.<sup>3</sup> Unilateral or bilateral asymmetric PH has rarely been associated with *FLNA* mutations,<sup>3</sup> but it is not known to be consistently related to any specific syndrome. FXS should be considered in the differential diagnosis of patients with PH.

#### Acknowledgment

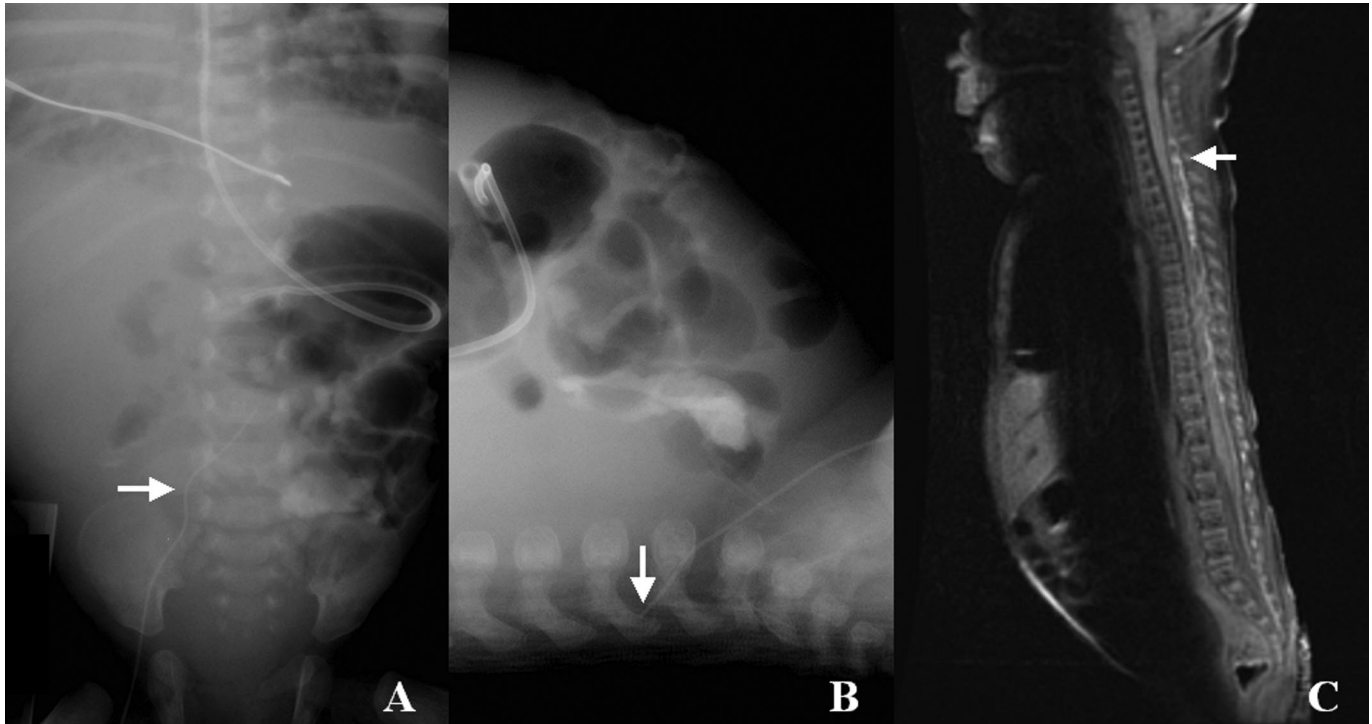
The authors thank the patients and their families.

#### References

1. Jin P, Warren ST. New insights into fragile X syndrome: from molecules to neurobehaviors. *Trends Biochem Sci* 2003;28:152-158.
2. Fox JW, Lamperti ED, Eksiöglu YZ, et al. Mutations in filamin 1 prevent migration of cerebral cortical neurons in human periventricular heterotopia. *Neuron* 1998;21:1315-1325.
3. Guerrini R, Filippi T. Neuronal migration disorders, genetics, and epileptogenesis. *J Child Neurol* 2005;20:287-299.
4. Oberle J, Rousseau F, Heitz D, et al. Instability of a 550-base pair DNA segment and abnormal methylation in fragile X syndrome. *Science* 1991;252:1097-1102.

5. Guerrini R, Mei D, Sisodiya S, et al. Germline and mosaic mutations of FLN1 in men with periventricular heterotopia. *Neurology* 2004;63:51–56.
6. Hessl D, Rivera SM, Reiss AL. The neuroanatomy and neuroendocrinology of fragile X syndrome. *Ment Retard Dev Disabil Res Rev* 2004;10:17–24.
7. Hinton VJ, Brown WT, Wisniewski K, Rudelli RD. Analysis of neocortex in three males with the fragile X syndrome. *Am J Med Genet* 1991;41:289–294.

8. Dunn HG, Renpenning H, Gerrard JW, Miller JR, Tabata T, Federof S. Mental retardation as a sex-linked defect. *Am J Ment Defic Res* 1963;67:827–848.
9. Desai HB, Donat J, Shokeir MH, Munoz DG. Amyotrophic lateral sclerosis in a patient with fragile X syndrome. *Neurology* 1990;40:378–380.
10. Devys D, Lutz Y, Rouyer N, Bellocq JP, Mandel JL. The FMR-1 protein is cytoplasmic, most abundant in neurons and appears normal in carriers of a fragile X premutation. *Nat Genet* 1993;4:335–340.



*Figure. (A) AP view of the abdomen revealing a central venous line in the midline (arrow). (B) Lateral view of the abdomen demonstrating the central venous line within the lumbar spine (arrow). (C) T1-weighted sagittal image of the spine with hyperintensity evident in the epidural venous plexus (arrow).*

### Extravasation of hyperalimentation into the spinal epidural space from a central venous line

*M. Scott Perry, MD; and Lisa Billars, MD, Atlanta, GA*

A 7-week-old ex-33-week girl developed fever and seizure. Blood and urine cultures were negative. Lumbar puncture revealed milky-white fluid with normal laboratory values except an

elevated glucose (8,867 mg/dL, nl 40 to 70 mg/dL). Abdominal x-ray revealed migration of the right saphenous percutaneous central venous line (PCVL) (figure). MRI (figure) demonstrated hyperintensity within the spinal epidural plexus. Extravasation of hyperalimentation into the epidural space is a rare complication of PCVLs in neonates.<sup>1</sup> A PCVL enters the lumbar plexus by way of the ascending lumbar vein which connects to the common iliac vein at L4-5.

Copyright © 2006 by AAN Enterprises, Inc.

Disclosure: The authors report no conflicts of interest.

Address correspondence and reprint requests to Dr. Perry, Emory University Department of Pediatrics, Division of Child Neurology, 2015 Uppergate Drive, NE Atlanta, GA 30322; e-mail: scott\_perry@oz.ped.emory.edu

1. Vidwans A, Neumann DP, Hussain N, Rosenkrantz T, Sanders MR. Diagnosis and management of spinal epidural space extravasation complicating percutaneous central venous line placement in a premature infant: case report and review of literature. *Conn Med* 2000;64:79–82.

# Neurology<sup>®</sup>

## Extravasation of hyperalimentation into the spinal epidural space from a central venous line

M. Scott Perry and Lisa Billars

*Neurology* 2006;67;715

DOI 10.1212/01.wnl.0000219648.78038.5b

This information is current as of August 21, 2006

<b>Updated Information &amp; Services</b>	including high resolution figures, can be found at: <a href="http://n.neurology.org/content/67/4/715.full">http://n.neurology.org/content/67/4/715.full</a>
<b>References</b>	This article cites 1 articles, 0 of which you can access for free at: <a href="http://n.neurology.org/content/67/4/715.full#ref-list-1">http://n.neurology.org/content/67/4/715.full#ref-list-1</a>
<b>Subspecialty Collections</b>	This article, along with others on similar topics, appears in the following collection(s): <b>All Genetics</b> <a href="http://n.neurology.org/cgi/collection/all_genetics">http://n.neurology.org/cgi/collection/all_genetics</a> <b>Cortical dysplasia</b> <a href="http://n.neurology.org/cgi/collection/cortical_dysplasia">http://n.neurology.org/cgi/collection/cortical_dysplasia</a> <b>Trinucleotide repeat diseases</b> <a href="http://n.neurology.org/cgi/collection/trinucleotide_repeat_diseases">http://n.neurology.org/cgi/collection/trinucleotide_repeat_diseases</a>
<b>Permissions &amp; Licensing</b>	Information about reproducing this article in parts (figures, tables) or in its entirety can be found online at: <a href="http://www.neurology.org/about/about_the_journal#permissions">http://www.neurology.org/about/about_the_journal#permissions</a>
<b>Reprints</b>	Information about ordering reprints can be found online: <a href="http://n.neurology.org/subscribers/advertise">http://n.neurology.org/subscribers/advertise</a>

*Neurology*® is the official journal of the American Academy of Neurology. Published continuously since 1951, it is now a weekly with 48 issues per year. Copyright . All rights reserved. Print ISSN: 0028-3878. Online ISSN: 1526-632X.

