

Longitudinal fMRI study for locomotor recovery in patients with stroke

Abstract—The authors investigated bihemispheric motor network reorganization supporting locomotor recovery after stroke over time. They determined longitudinal changes in locomotor function and fMRI in 10 stroke patients at the subacute stage and the chronic stage. The results suggest that the bihemispheric reorganization mechanism underlying locomotor recovery evolved from the ipsilateral (contralesional) primary sensorimotor cortex (SM1) activation at the subacute stage to the contralateral (ipsilesional) SM1 activation at the chronic stage.

NEUROLOGY 2006;67:330–333

Y.H. Kim, MD, PhD*; S.H. You, PT, PhD*; Y.H. Kwon, PT, MS; M. Hallett, MD; J.H. Kim, PT, PhD; and S.H. Jang, MD

Since the introduction of functional neuroimaging techniques, the motor recovery mechanism for stroke patients has been elucidated.¹ In addition, several studies have been reported that cortical activities can change as motor recovery progresses in stroke patients.^{2–6} The clarification of such a relationship is important because results of such studies could guide new rehabilitation strategies for stroke patients. The majority of these studies focused on the interval changes with the motor recovery of upper extremity, and little is known about the cortical activation changes concurrent with locomotor recovery in stroke patients.^{2–7} Therefore, we investigated cortical activity changes occurring during locomotor recovery after stroke, using fMRI.

Methods. *Subjects.* We recruited 10 stroke patients (six men; mean age 50.0 years, SE = 2.7) and age-matched eight normal control subjects (four men; mean age 51.8 years, SE = 2.4). All subjects signed an ethical approval and informed consent form. Inclusion criteria for stroke patients were 1) first-ever stroke, 2) complete loss of muscle strength of the paretic lower extremity at the onset of stroke but recovered to the extent of the ability to move the leg against gravity at least 3 weeks post-stroke, and 3) good locomotor recovery from the subacute to the chronic stage (more than 2 grade on the Modified Motor Assessment Scale [MMAS]).

*Authors contributed equally to this work.

From the Department of Physical Medicine and Rehabilitation (Y.H. Kim), Sungkyunkwan University School of Medicine, Samsung Medical Center, Seoul, Republic of Korea; Physical Therapy Program (S.H.Y.), Hampton University, Hampton, VA; Department of Rehabilitation Science (Y.H. Kwon, J.H. Kim), Daegu University Taegu, Republic of Korea; Human Motor Control Section (M.H.), National Institute of Neurological Disorders and Stroke, Bethesda, MD; and Department of Physical Medicine and Rehabilitation (S.H.J.), School of Medicine, Yeungnam University, Taegu, Republic of Korea.

Supported by a grant (M103KV010014 03K2201 01430) from the Brain Research Center of the 21st Century Frontier Research Program funded by the Ministry of Science and Technology of Republic of Korea.

Disclosure: The authors report no conflicts of interest.

Received November 11, 2005. Accepted in final form March 23, 2006.

Address correspondence and reprint requests to Dr. Sung Ho Jang, Department of Physical Medicine and Rehabilitation, College of Medicine, Yeungnam University, 317-1 Daemyungdong, Namku, Taegu, 705-717, Republic of Korea; e-mail: strokerehab@hanmail.net

Locomotor function evaluation. Standardized Motoricity Index (MI) (lower extremity only) and MMAS (walking item only) were used to determine locomotor function. MI is a measure of integrity of lower extremity motor function with a maximum score of 100. MMAS was used to assess locomotor function. Each item is scored on a scale from 0 (unable to stand or walk) to 6 (walk up and down four steps). The reliability and validity for the MI and MMAS are well established.^{8,9}

fMRI. fMRI was performed in stroke patients twice and control subjects once. The first fMRI for stroke patients was performed when the patients were able to extend the knee against gravity (average time, 5.4 weeks), and the second fMRI was performed at 6 months from onset. The subject's head, trunk, pelvis, and hip were secured to prevent any motion artifact using a customized immobilizing frame. The task involved sequential knee flexion-extension with a predetermined angle of 0 to 60 degrees at a metronome-controlled frequency of 0.5 Hz (cycle of 15 seconds of rest and 15 seconds of stimulus).

The blood oxygenation level-dependent (BOLD) fMRI measurement, which employs the echo-planar imaging (EPI) technique, was performed using a 1.5-T MR scanner (Vision, Siemens, Erlangen, Germany) with a standard head coil. For the anatomic base images, 20 axial, T1-weighted, conventional, 5 mm thick, spin-echo images were obtained with a matrix size = 128 × 128 and a field of view (FOV) = 210 mm, parallel to the bicommissure line of the anterior commissure-posterior commissure. EPI BOLD images were acquired over the same 20 axial sections for each epoch, producing a total of 1,200 images for each subject. Imaging parameters for each experiment consisted of TR/TE = 3,000 msec/60 msec, FOV = 210 mm, matrix size = 64 × 64, and slice thickness = 5 mm. fMRI data were analyzed using SPM-99 software. Statistical parametric maps were obtained and voxels were considered significant at a threshold of $p < 0.05$, corrected. A laterality index (LI) was used to determine any shift in the symmetry of cortical activation between the two hemispheres for the region of interest (ROI): SM1, premotor cortex (PMC), supplementary motor area (SMA), posterior parietal cortex, cerebellum, and vermis.^{1,10} LI is expressed as $(C - I)/(C + I)$, where C = contralateral (ipsilesional) activation and I = ipsilateral (contralesional) activation.

Statistical analysis. A separate Wilcoxon signed rank test for two related samples was used to evaluate changes in the MI and MMAS. LI changes of the paretic leg from the subacute stage to chronic stage were determined and compared with those of controls and nonparetic leg. Spearman's R statistics were computed to determine any direct relationship between the locomotor function changes and LI score. Significance level was set at $p < 0.05$.

Results. *Locomotor function data.* A separate Wilcoxon signed rank test revealed changes in MI and MMAS scores ($p < 0.05$), suggesting that over the course of the recovery period, mean locomotor function recovered from poor ambulation to normal or close to normal ambulation (table 1).

Table 1 Patient demographic and clinical data

Patients	Sex/age	Lesion location	Risk factors	Time fMRI acquired		MI		MMAS	
				Subacute (wk)	Chronic (mo)	Subacute	Chronic	Subacute	Chronic
1	M/43	R CR infarct	Cig	4	6	47	91	3	6
2	F/60	R CR infarct	NIDDM, HTN, Hchol	6	6	47	85	2	5
3	M/42	R CR & BG hemorrhage	NIDDM, HTN, Hchol	6	6	37	49	2	5
4	M/59	R CR infarct	NIDDM, HTN	6	6	37	83	2	5
5	F/45	R CR & BG hemorrhage	HTN	6	6	37	49	3	5
6	F/62	R CR & BG hemorrhage	NIDDM, HTN	5	6	47	91	3	6
7	M/40	R CR infarct	HTN	4	6	47	91	3	6
8	M/54	R CR & BG hemorrhage	NIDDM, HTN, Hchol, Cig	6	6	37	49	2	4
9	F/56	L CR & BG hemorrhage	HTN, Hchol	6	6	37	85	2	5
10	M/39	L CR & BG hemorrhage	NIDDM, HTN	5	6	51	91	3	6
Mean	50			5.4	6.0	42.2	76.4	2.5	5.3
SEM	2.9			0.3	0.0	1.8	6.1	0.2	0.2
<i>p</i> Value							0.005		0.003

MI = Motoricity Index; MMAS = Modified Motor Assessment Scale; CR = corona radiata; BG = basal ganglia; NIDDM = non-insulin-dependent diabetes mellitus; HTN = hypertension; Afib = atrial fibrillation; Hchol = hypercholesterolemia; Cig = cigarette smoking; SEM, standard error measurement.

Neuroimaging data. Normal control subjects showed activation in the contralateral SM1, PMC, and the ipsilateral cerebellum. There was no difference in regional activation between the right and the left leg ($p > 0.05$). The mean (SD) LI for SM1 was 0.85 (0.07) for right leg and 0.81(0.10) for left leg.

In the subacute stage, the paretic leg movement was associated with regional activation similar to that of control subjects, but ipsilateral SM1 and SMA were coactivated (figure). In the chronic stage, the recovered paretic leg movement was associated with an increased activation in the contralateral SM1 and a relative disappearance in the ipsilateral SMA, PMC, and cerebellum activation ($p < 0.05$). The nonparetic leg movement activated regions sim-

ilar to those of the control subjects, but SMA activation was present as seen in the paretic leg movement.

In the stroke patients, among the LIs in the ROIs, the LI in the SM1 increased over time for the paretic leg, but did not change for the nonparetic leg (table 2). This difference was significant. In the subacute stage of recovery in the paretic leg, the leg movement induced slightly higher in the ipsilateral activation than the contralateral SM1 activation, resulting in a mean (SD) SM1 LI score of -0.02 (0.17). The nonparetic leg in the subacute stage, in contrast, had a mean (SD) SM1 LI of 0.87 (0.66). In the chronic stage, the mean (SD) SM1 LI for the paretic leg was 0.68 (0.20) and 0.82 (0.1) for the nonparetic leg. The interval change of the LI for SM1

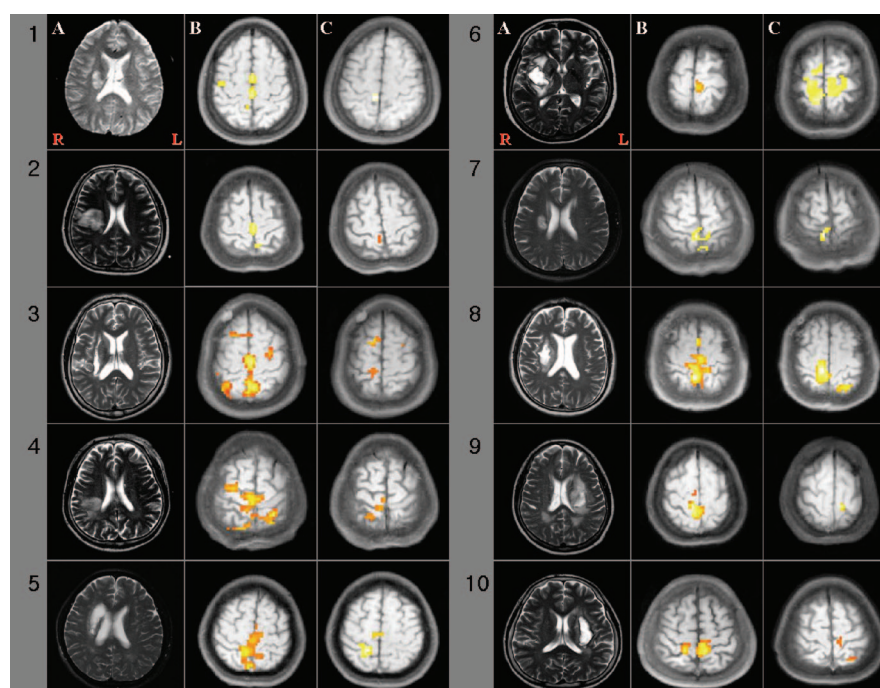


Figure. Cortical reorganization illustrated in fMRI. The A columns represent T2-weighted diagnostic images. The B and C columns represent fMRI images obtained at the subacute stage and the chronic stage of locomotor recovery. The unaffected primary sensorimotor cortex was activated in all patients at the subacute stage, but decreased in five patients (Patients 3, 5, 6, and 8) and disappeared in five patients (Patients 1, 2, 4, 7, 9, and 10) at the chronic stage.

Table 2 Change in laterality index for each region of interest with locomotor recovery

Affected leg movement	SM1		SMA		PMC		PPC		CBL		Vermis	
	Subacute	Chronic	Subacute	Chronic	Subacute	Chronic	Subacute	Chronic	Subacute	Chronic	Subacute	Chronic
1	0.27	1.00	-0.14	0.00	0.00	0.00	0.00	0.00	0.00	0.00	0.00	0.00
2	-0.49	1.00	-0.43	0.00	1.00	0.00	0.00	0.00	0.00	0.00	-1.00	0.00
3	-0.13	-0.93	-0.23	-0.45	0.00	0.53	0.00	0.09	-1.00	-1.00	-0.23	0.42
4	0.34	1.00	0.28	1.00	-0.67	0.00	0.00	0.00	1.00	0.00	-0.31	1.00
5	0.62	0.74	-0.08	-0.22	0.00	0.00	0.00	0.00	0.00	0.00	0.62	-1.00
6	-1.00	0.08	-1.00	0.32	0.00	0.00	0.00	0.00	0.00	-1.00	0.00	0.00
7	0.29	10.00	0.43	0.00	-1.00	0.00	0.00	0.00	0.00	0.00	-0.33	0.00
8	0.26	0.86	-0.47	1.00	1.00	0.00	0.00	0.00	0.00	0.00	0.43	-1.00
9	-0.68	1.00	-0.72	0.00	0.00	0.00	0.00	0.00	0.00	0.00	0.00	0.00
10	0.32	1.00	0.31	1.00	-1.00	0.00	0.00	0.00	0.00	0.00	0.00	1.00
Mean	-0.02	0.68	-0.21	0.27	-0.07	0.05	0.00	0.01	0.00	-0.20	-0.08	0.04
SEM	0.17	0.20	0.15	0.17	0.22	0.05	0.00	0.01	0.15	0.13	0.14	0.21
<i>p</i> Value	0.04		0.06		0.16		0.87		0.75		0.32	
Nonaffected leg movement												
1	1.00	1.00	0.00	0.00	0.00	0.00	0.00	0.00	0.00	0.00	1.00	0.00
2	1.00	0.29	0.00	0.00	0.00	0.00	0.00	0.00	0.00	0.00	1.00	0.00
3	1.00	1.00	0.00	0.00	0.00	0.00	0.00	0.00	0.00	0.00	0.00	0.00
4	1.00	1.00	0.00	0.00	0.00	0.00	0.00	0.00	0.00	0.00	-1.00	0.42
5	0.67	1.00	0.00	0.00	0.00	0.52	0.00	0.00	0.00	0.00	-1.00	1.00
6	1.00	1.00	1.00	0.00	0.00	0.00	0.00	0.00	0.00	0.00	.33	1.00
7	1.00	1.00	0.00	0.47	0.00	0.00	0.00	0.00	0.00	0.00	0.89	1.00
8	1.00	0.54	0.00	1.00	-1.00	0.00	0.00	0.00	0.00	0.00	-1.00	1.00
9	0.56	0.33	0.00	0.00	0.00	0.00	0.00	0.00	0.00	0.00	1.00	0.15
10	0.50	1.00	1.00	0.54	0.00	1.00	0.00	0.00	0.00	0.00	1.00	1.00
Mean	0.87	0.82	0.20	0.20	-0.10	0.15	0.00	0.00	0.00	0.00	0.22	0.56
SEM	0.07	0.10	0.13	0.11	0.10	0.11	0.00	0.00	0.00	0.00	0.27	0.15
<i>p</i> Value	0.69		0.86		1.00		0.40		0.10		1.00	

SM1 = primary sensorimotor cortex; SMA = supplementary motor area; PMC = premotor cortex; PPC = posterior parietal cortex; CBL = cerebellum; SEM = standard error measurement.

was correlated with the MI ($r = 0.63, p < 0.05$) and MMAS ($r = 0.70, p < 0.05$) scores.

Discussion. We demonstrate interhemispheric reorganization underlying locomotor recovery after stroke. Because our study is the first longitudinal fMRI observation to demonstrate a progression of the LI from the subacute stage to the chronic stage, there are no data to compare with our present findings. In either case, the regions of activation observed in control subjects during leg movement were similar to those seen in the nonparetic leg in stroke patients. In the subacute stage, our leg movement-related activation was evident in the bilateral hemisphere. Later in the chronic stage, the significant LI increase reflects a combined phenomenon of a reduction in contralesional (ipsilateral hemisphere) activity and an increase in ipsilesional (contralateral hemisphere) activity.

Although the mechanism of locomotor recovery in stroke remains unclear, our results support the previous finding that SM1 activation shifted from the unaffected hemisphere to the affected hemisphere associated with motor recovery of the upper extremity.^{2,4-6} Our fMRI observation was also com-

patible with a spectroscopic topography study that showed increased contralateral SM1 activation as locomotor recovery proceeded.⁷ The present data combined with the previous findings²⁻⁶ suggest that ipsilateral motor tract is accountable, in part, for the mechanism of such an altered bihemispheric activation in the early stage of locomotor recovery. The enhanced SM1 activation in the affected hemisphere may be one common mechanism underlying motor recovery after stroke.

References

1. Cramer SC, Nelles G, Benson RR, et al. A functional MRI study of subjects recovered from hemiparetic stroke. *Stroke* 1997;28:2518-2527.
2. Marshall RS, Perera GM, Lazar RM, et al. Evolution of cortical activation during recovery from corticospinal tract infarction. *Stroke* 2000;31:656-661.
3. Calautti C, Leroy F, Guincestre JY, et al. Dynamics of motor network overactivation after striatocapsular stroke: a longitudinal PET study using a fixed-performance paradigm. *Stroke* 2001;32:2534-2542.
4. Feydy A, Carlier R, Roby-Brami A, et al. Longitudinal study of motor recovery after stroke: recruitment and focusing of brain activation. *Stroke* 2002;33:1610-1617.
5. Jang SH, Kim YH, Cho SH, et al. Cortical reorganization associated with motor recovery in hemiparetic stroke patients. *Neuroreport* 2003;14:1305-1310.
6. Jang SH, Cho SH, Kim YH, et al. Cortical activation changes associated with motor recovery in patients with precentral knob infarct. *Neuroreport* 2004;15:395-399.

7. Miyai I, Yagura H, Hatakenaka M, et al. Longitudinal optical imaging study for locomotor recovery after stroke. *Stroke* 2003;34:2866–2870.
8. Demeurisse G, Demol O, Robaye E. Motor evaluation in vascular hemiplegia. *Eur Neurol* 1980;19:382–389.

9. Loewen SC, Anderson BA. Reliability of the Modified Motor Assessment Scale and the Barthel Index. *Phys Ther* 1988;68:1077–1081.
10. Dassonville P, Lewis SM, Zhu XH, et al. Effects of movement predictability on cortical motor activation. *Neurosci Res* 1998;32:65–74.

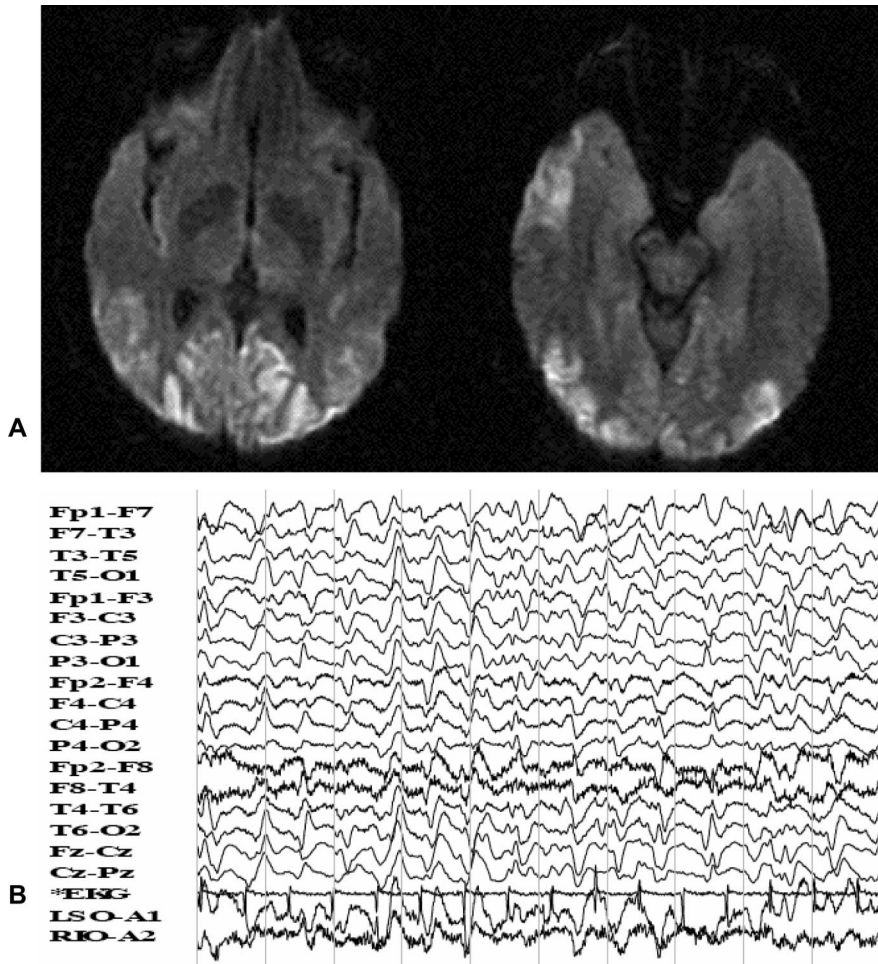


Figure. (A) Diffusion-weighted MRI (DWI) showing ribbon-shaped hyperintense signals in the occipital and right temporal lobes. DWI is valuable for diagnosis of Creutzfeldt–Jakob disease.² DWI is more tolerant of motion artifacts than T2WI and fluid attenuated inversion recovery images, making it superior in patients with myoclonic jerks. Similar DWI changes can be seen in anoxia, reversible posterior leukoencephalopathy syndrome, and CNS vasculitis. The basal ganglia are spared. (B) EEG revealing runs of bihemispheric, periodic sharp wave complexes.

MRI and EEG findings in Heidenhain variant of Creutzfeldt–Jakob disease

Salah G. Keyrouz, MD; Bishoy T. Labib, MD; and Rajesh Sethi, MD, Little Rock, AR

A 51-year old woman was admitted with rapidly progressive memory loss, language impairment, and difficulty performing rou-

tine daily activities. Prior to admission, she was on a psychiatric ward because of visual hallucinations and abnormal behavior. She was aphasic, cortically blind and spastic with exaggerated reflexes, bilateral Babinski, and frequent multifocal myoclonic jerks. CSF 14-3-3 protein was elevated. The patient died 4 months after unrelenting progression. This patient had probable sporadic Creutzfeldt–Jakob disease (CJD), Heidenhain variant.¹ The leading symptoms of a visual disorder and rapid progression have been referred to as the “Heidenhain variant” of CJD since 1954. It shows the most pronounced neuropathologic/radiologic changes in the occipital lobes (figure).

Copyright © 2006 by AAN Enterprises, Inc.

Disclosure: The authors report no conflicts of interest.

Address correspondence and reprint requests to Dr. Bishoy T. Labib, Department of Neurology, University of Arkansas for Medical Sciences, 4301 West Markham Street, Slot 500, Little Rock, AR 72205; e-mail: labibbishoy@uams.edu

1. Kropp S, Schulz-Schaeffer W, Finkenstaedt M, et al. The Heidenhain variant of Creutzfeldt–Jakob Disease. *Arch Neurol* 1999;56:55–61.
2. Shiga Y, Miyazawa K, Sato S, et al. Diffusion-weighted MRI abnormalities as an early diagnostic marker for Creutzfeldt–Jakob disease. *Neurology* 2004;63:443–449.

Neurology[®]

MRI and EEG findings in Heidenhain variant of Creutzfeldt–Jakob disease

Salah G. Keyrouz, Bishoy T. Labib and Rajesh Sethi

Neurology 2006;67;333

DOI 10.1212/01.wnl.0000208487.18608.41

This information is current as of July 24, 2006

Updated Information & Services	including high resolution figures, can be found at: http://n.neurology.org/content/67/2/333.full
References	This article cites 2 articles, 1 of which you can access for free at: http://n.neurology.org/content/67/2/333.full#ref-list-1
Subspecialty Collections	This article, along with others on similar topics, appears in the following collection(s): EEG http://n.neurology.org/cgi/collection/eeg_ MRI http://n.neurology.org/cgi/collection/mri Prion http://n.neurology.org/cgi/collection/prion
Permissions & Licensing	Information about reproducing this article in parts (figures, tables) or in its entirety can be found online at: http://www.neurology.org/about/about_the_journal#permissions
Reprints	Information about ordering reprints can be found online: http://n.neurology.org/subscribers/advertise

Neurology® is the official journal of the American Academy of Neurology. Published continuously since 1951, it is now a weekly with 48 issues per year. Copyright . All rights reserved. Print ISSN: 0028-3878. Online ISSN: 1526-632X.

