

Symmetric basal ganglia calcification in a 9-year-old child with MELAS

Sheng-Horng Chung, MD; Shyr-Chyr Chen, MD;
Wen-Jone Chen, MD, PhD; and Chien-Chang Lee, MD, MSc

A 9-year-old boy presented with headache, vomiting, and leftward eye gaze deviation. On examination, left homonymous hemianopia, horizontal nystagmus, and anisocoric pupils were noted. Brain CT disclosed symmetric calcification in basal ganglia (figure A). Blood examination showed lactic acidemia. Further MRI revealed right occipito-temporo-parietal cortical hyperintensities (figure, B and C). Muscle biopsy revealed ragged-red fibers, and genetic study showed an A3243G point mutation, confirming the diagnosis of mitochondrial encephalomyopathy, lactic acidosis, and strokelike symptoms (MELAS). Symmetric basal ganglia calcification, focal cerebral lesions not confined to the vascular territories in a young patient warrant further workup for mitochondrial cytopathy.^{1,2}

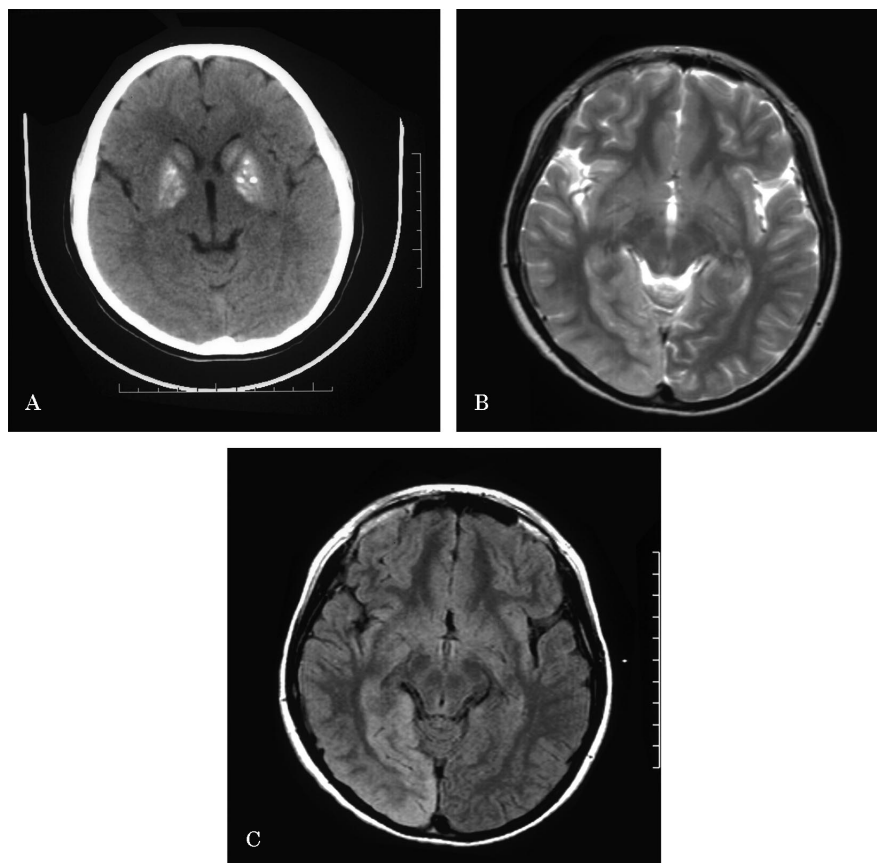


Figure. (A) CT image of brain shows symmetric bilateral hyperintensities in bilateral putamen, globus pallidus, and caudate head. (B) T2-weighted axial MRI shows areas of hyperintensities over peripheral parenchyma of right occipital, temporal, and parietal lobes. (C) Axial fluid-attenuated inversion recovery MRI shows right occipital, temporal, and parietal peripheral parenchyma hyperintensities, which do not correlate with vascular territories.

References

1. Valanne L, Ketonen L, Majander A, Suomalainen A, Pihko H. Neuroradiologic findings in children with mitochondrial disorders. *Am J Neuroradiol* 1998;19:369-377.
2. Sue CM, Crimmins DS, Soo YS, et al. Neuro-radiological features of six kindreds with MELAS tRNA (Leu) A2343G point mutation: implications for pathogenesis. *J Neurol Neurosurg Psychiatry* 1998;65:233-240.

From the Department of Emergency Medicine, National Taiwan University Hospital, Taipei.

Disclosure: The authors report no conflicts of interest.

Address correspondence and reprint requests to Dr. Chien-Chang Lee, Department of Emergency Medicine, National Taiwan University Hospital, No.7 Chun-Shan South Road, Taipei, 100, Taiwan; e-mail: chnchnlee@ha.mc.ntu.edu.tw

Neurology[®]

Symmetric basal ganglia calcification in a 9-year-old child with MELAS

Sheng-Horng Chung, Shyr-Chyr Chen, Wen-Jone Chen, et al.

Neurology 2005;65;E19

DOI 10.1212/01.wnl.0000184112.34211.d1

This information is current as of November 7, 2005

Updated Information & Services	including high resolution figures, can be found at: http://n.neurology.org/content/65/9/E19.full
Supplementary Material	Supplementary material can be found at: http://n.neurology.org/content/suppl/2007/04/02/65.9.E19.DC1
References	This article cites 2 articles, 1 of which you can access for free at: http://n.neurology.org/content/65/9/E19.full#ref-list-1
Subspecialty Collections	This article, along with others on similar topics, appears in the following collection(s): Basal ganglia http://n.neurology.org/cgi/collection/basal_ganglia Mitochondrial disorders http://n.neurology.org/cgi/collection/mitochondrial_disorders MRI http://n.neurology.org/cgi/collection/mri
Permissions & Licensing	Information about reproducing this article in parts (figures, tables) or in its entirety can be found online at: http://www.neurology.org/about/about_the_journal#permissions
Reprints	Information about ordering reprints can be found online: http://n.neurology.org/subscribers/advertise

Neurology® is the official journal of the American Academy of Neurology. Published continuously since 1951, it is now a weekly with 48 issues per year. Copyright . All rights reserved. Print ISSN: 0028-3878. Online ISSN: 1526-632X.

