

Do generalized tonic-clonic seizures in infancy exist?

Christian Korff, MD; and Douglas R. Nordli, Jr., MD

Abstract—Objective: To determine the frequency of generalized tonic-clonic seizures (GTCS) in infants (1 month to 2 years). **Methods:** From a total of 2,112 patients monitored in our video-EEG lab from May 2000 through January 2005, 109 distinct seizures in 77 infants were reviewed. Eight events in eight patients were excluded because of video files insufficiently reliable to determine the clinical characteristics with precision. The clinical manifestations and electrographic features of the remaining 101 seizures in 69 infants were retrospectively analyzed. **Results:** The authors did not observe a single GTCS. Four patients had icti that resembled GTCS, but careful analysis of these episodes revealed that three of them had a focal onset and that the fourth had a slightly different sequence of events. **Conclusions:** Generalized tonic-clonic seizures are rarely, if ever, seen in infants younger than age 2 in a tertiary-care pediatric epilepsy unit. Instead, they more commonly occur in older children, particularly in the well-characterized epilepsy syndromes of childhood and adolescence.

NEUROLOGY 2005;65:1750–1753

The term “generalized tonic-clonic seizure” (GTCS) connotes a specific sequence characterized by diffuse tonic posturing followed by generalized clonus or rhythmic jerking of all limbs. It is probably a familiar term to all physicians, but it is sometimes mistakenly used to describe any type of convulsive activity. Its proper recognition is important because, when present, it suggests certain epilepsy syndromes and can impact selection of medication.

We were aware that infants had a different repertoire of seizures than older children and adults. It was our impression, moreover, that infantile GTCS were very unusual so we sought to determine their frequency from our infantile ictal data base. We reviewed the literature for reports of infantile GTCS and carefully scrutinized the definitions of the infantile epilepsies for descriptions of infantile GTCS.

Methods. The database of the Epilepsy Center at Children’s Memorial Hospital (CMH), Chicago, IL, includes patients ages 1 day to 18 years, who present with a great diversity of indications, ranging from new-onset paroxysmal spells to intractable epileptic seizures. Patients are mainly referred through pediatricians, pediatric neurologists, and pediatric epileptologists.

Twenty-three gold electrodes are used for all recordings, including a reference and a ground, and placed according to the rules of the 10–20 International System. All recordings are interpreted by a pediatric epileptologist at CMH. The seizures were classified according to the International League Against Epilepsy scheme,¹ to which we added different subtypes for each category. For instance, spasms that exhibited unequivocal generalized clin-

ical and electrographic features were classified under generalized seizures (table 1).

From a total of 2,112 patients monitored in our video-EEG lab from May 2000 through January 2005, 109 distinct seizures in 77 infants (1 month to 2 years) were retrospectively reviewed. In most cases, our patients had a single seizure type recorded. A minority of the patients had several seizure types reported, and parental descriptions of events consistent with GTCS were extremely rare. If several seizures were recorded during the same EEG, only one seizure type per EEG was considered. Eight events in eight patients were excluded, because of video files insufficiently reliable to determine the clinical characteristics with precision. We analyzed the clinical manifestations and electrographic features of the remaining 101 seizures in 69 infants.

Results. The types of seizures that we observed are presented in table 1. We found that only four patients had icti that resembled GTCS. Careful analysis of these episodes revealed that three of them had a focal onset and that the fourth had a slightly different sequence of events.

The first patient was a 7-month-old developmentally normal girl admitted after two convulsions in the context of a febrile otitis media. The recorded seizure started with a symmetric tonic posture, followed by bilateral clonus. Careful examination of the clinical features revealed that the clonus was actually asymmetric, predominant on the left side. Electrographically, the event was characterized by focal spikes in the right frontal region at onset (see figure E-1A on the *Neurology* Web site; go to www.neurology.org), followed by ipsilateral posterior and contralateral homotopic spread (see figure E-1B) and secondary generalization (see figure E-1C and E-1D). Additional workup included a cerebral MRI and a lumbar puncture but did not reveal a specific etiology. This patient was diagnosed with idiopathic localization-related epilepsy.

The second patient was a 10-month-old developmentally

Additional material related to this article can be found on the *Neurology* Web site. Go to www.neurology.org and scroll down the Table of Contents for the December 13 issue to find the title link for this article.

From the Epilepsy Center, Children’s Memorial Hospital, Chicago, IL.

Supported by a scholarship from the Eugenio Litta Foundation, Vaduz, Liechtenstein (C.M.K.).

Disclosure: The authors report no conflicts of interest.

Received June 7, 2005. Accepted in final form August 16, 2005.

Address correspondence and reprint requests Dr. D.R. Nordli, Jr., Epilepsy Center, Children’s Memorial Hospital, Box 29, 2300 Children’s Plaza, Chicago, IL 60614-3394; e-mail: dnordli@childrensmemorial.org

1750 Copyright © 2005 by AAN Enterprises, Inc.

Table 1 Types of seizures in infants observed at Children's Memorial Hospital Epilepsy Center

Seizure type	n (%), total = 101
Generalized	
Clonic	6 (5.9)
Clonic-tonic-clonic	1 (1)
Atonic	5 (5)
Spasms	13 (12.9)
Partial	
Tonic-clonic with secondary generalization	3 (3)
Pure behavioral arrest	1 (1)
Behavioral arrest and version	11 (10.9)
Clonic	11 (10.9)
Tonic	10 (9.9)
Tonic-clonic	2 (2)
Hypermotor	1 (1)
Unclassified	
Spasms with focal seizures/asymmetric	28 (27.7)
Diffuse tonic/focal clonic	3 (3)
Migratory	6 (5.9)

normal girl admitted for new-onset repeated paroxysmal events described by her parents as bilateral tonic stiffening of the arms and mouth automatisms. The recorded seizures were described by the initial reviewer as a diffuse tonic posture, mouth automatisms, and coarse trembling. More careful analysis of the ictal semiology revealed that the tonic stiffening was asymmetric, that some head version was present, and that the trembling represented subtle unilateral myoclonus. Electrographically, the events were characterized by a unilateral central onset of monomorphic rhythmic theta-alpha (RTA) activity (see figure E-2A), evolving into secondarily generalized spike-and-wave complexes (see figure E-2B and E-2C). This patient was diagnosed with symptomatic localization-related epilepsy by virtue of the precise localization of the seizure and dissimilarity of the ictal semiology to reported cases of idiopathic localization-related epilepsy in infants; however, idiopathic localization-related epilepsy remains a possibility.

The third patient was an 11-month-old developmentally normal boy with new-onset paroxysmal events. His recorded seizure was clinically characterized by bilateral clonus and blinking. The onset was off-camera, but it was correlated with low-voltage fast activity on the EEG (see figure E-3A), a pattern that usually accompanies tonic stiffening. This pattern was predominant on one hemisphere and was followed by unilateral rhythmic theta posterior spikes (see figure E-3A), anterior and contralateral spread (see figure E-3B and E-3C). This patient was diagnosed with idiopathic localization-related epilepsy.

The fourth patient was a 9-month-old developmentally normal girl, who had presented with head drops and focal clonic seizures involving either side since age 4 months.

One of her recorded seizures was characterized by brief bilateral symmetric clonus and blinking, followed by a

symmetric tonic posture, erratic clonus, and orolimentary automatisms. Its electrographic correlate was a short run of generalized sharp waves, some attenuation, bilateral but right predominant midline-temporal RTA (see figure E-4A), with spread over both hemispheres (see figure E-4B through E-4D). This event was considered as a clonic-tonic-clonic seizure. Subsequent evolution of the child's course has strongly suggested that the child has Dravet syndrome.

Discussion. In this retrospective study of 101 seizures in 69 infants aged 1 month to 2 years, we did not observe a single GTCS. Four infants had events that clinically resembled GTCS. In three cases, we found that seizures were actually focal seizures with various degrees of secondary generalization. The fourth event had a generalized clinical and electrographic onset, but started with a clonic phase, followed by tonic stiffening and ended with a second clonic phase. This clonic-tonic-clonic sequence has been observed in idiopathic generalized epilepsies such as myoclonic-astatic epilepsy as described by Doose and in other infantile epilepsies such as Dravet syndrome.

Our observations in a tertiary-care pediatric epilepsy unit are consistent with previous reports. Placed in the perspective of a review of the literature, we think that these results can be reasonably extended to the general child population. Notably, not a single GTCS was observed in a study on 296 seizures in 76 children younger than 3 years.²

Reports on GTCS in infants younger than 2 years are extremely sparse. They were part of the variable seizure phenotype described in a kindred of 69 patients with benign familial neonatal convulsions, but ictal video-EEG data demonstrating generalized suppression at onset followed by symmetric rhythmic slow waves and diffuse spikes was only reported in two patients, one of whom exhibited tonic-clonic manifestations.³ A similar electroclinical pattern was reported in two neonates with nonbenign familial neonatal convulsions.⁴ EEG features nearly identical to those in our first three patients were described in a 5-day-old infant with benign neonatal convulsions. His seizures were described as GTCS and consisted in tonic extension of arms and legs, cyanosis, and clonic jerks. This patient, however, also presented with eye deviation to the right side and the electrographic correlate to the events, described as generalized, had a unilateral onset in the frontocentral area on either side.⁵ These signs point to focal seizures with secondary generalization.

An increasing number of epilepsy syndromes that present in infancy have been recognized. Some, such as myoclonic astatic epilepsy and Dravet syndrome, include GTCS in their phenotype. However, even in these entities, GTCS are rarely observed before age 2. Moreover, a recent video-EEG correlate description of seizures in Dravet syndrome showed that most convulsions were actually not generalized, but instead exhibited subtle focal features. Some of them

were clinically characterized by bilateral asymmetric tonic stiffening, followed by bilateral asynchronous clonic jerks of asymmetric frequency, with asymmetric corresponding electrographic features. The authors used the term “falsely generalized seizures” to describe these events. The other ones, named “unstable seizures” by the authors, were characterized by discharge localization changes during the same seizure and were thought to represent focal seizures emanating from several foci that fired successively. Rare truly generalized convulsions were also described, but the age at which they were observed is not mentioned in the report.⁶

GTCS accounted for up to 80% of febrile seizures in a recently reported series of patients.⁷ However, the age at observation was not specified and no EEG correlate was available in this report. Other authors emphasize the fact that the descriptions of febrile seizures in children are almost exclusively based on the observations of their parents,² which are most of the times not accurate enough to determine whether there was a focal or a generalized onset.

Large-scale childhood epilepsy epidemiologic studies also lack details about the age at which GTCS are observed; most do not specifically delineate and analyze a group of infants under 2 years or group tonic, clonic, and tonic-clonic seizures together.⁸⁻¹⁰ These studies, moreover, do not have the benefit of concurrent video-EEG.

The rarity of GTCS in infants younger than 2 years is thought to be related to the relative immaturity and lack of organization of their developing brain, characterized by variable neuronal excitability, imperfect myelination, and incomplete inter-hemispheric connections.¹¹ This maturational concept is recognizable on EEG recordings in infants, as normal electrographic features follow a fairly stereotyped evolution during the first years of life. In particular, tight synchronization of vertex waves, sleep spindles, and K complexes do not normally appear in infants younger than 2 years. The implication is that it may not be possible to generate well-formed highly synchronized or generalized discharges in this population. Generalized tonic-clonic seizures are an important type of seizures seen in epileptic syndromes that present in older children and in adolescents (table 2), but most, if not all infantile seizures that appear to be generalized tonic-clonic are really focal with secondary generalization.

Patients with partial seizures of unknown etiology occurring in the first 2 years of life and benign neurodevelopmental outcome were described in 1963.¹² More recently, seven patients with benign idiopathic partial epilepsy ages 3 to 20 months at onset were reported. Their events were characterized by staring or motion arrest followed by generalized tonic and clonic phases but proved to be partial seizures with secondary generalization on EEG. These events were correlated to focal discharges of rhythmic spikes or low-voltage fast activity followed by recruiting

Table 2 Epileptic syndromes that present in older children and in adolescents with generalized tonic-clonic seizures as part of their phenotype

Epilepsy syndrome	Usual age at observation of GTCS, y
Childhood absence epilepsy	10–15
Juvenile myoclonic epilepsy	16
Juvenile absence epilepsy	12–14
Epilepsy with GTCS on awakening	14–16
GEFS+	>6

GTCS = generalized tonic-clonic seizures; GEFS+ = generalized epilepsy with febrile seizures +.

rhythms and some degree of secondary bilateral synchronization.¹³ A family history of similar seizures at the same age is frequent among these patients, but in a study comparing sporadic cases with patients with a positive family history, no electroclinical differences were found between both groups.¹⁴ Certain authors grouped these patients under the single name of “benign familial infantile seizures.”¹⁵ We believe our first three cases belong to this epileptic syndrome.

A major limitation in our study is that we may have a referral bias and that this information may not be truly indicative of the general population. The particular challenges of interpreting infantile seizures may require concurrent EEG analysis to be certain of the true nature of the ictal events. Indeed, physicians need to be cautious about inferring too much regarding the nature of infantile seizures from clinical descriptions. Instead, and particularly in the refractory patient population, video-EEG monitoring may be helpful in better characterizing the disorder.

References

- Commission on Classification and Terminology of the International League Against Epilepsy. Proposal for revised clinical and electroencephalographic classification of epileptic seizures. *Epilepsia* 1981;22:489–501.
- Hamer HM, Wyllie E, Luders HO, Kotagal P, Acharya J. Symptomatology of epileptic seizures in the first three years of life. *Epilepsia* 1999;40:837–844.
- Ronen GM, Rosales TO, Connolly M, Anderson VE, Leppert M. Seizure characteristics in chromosome 20 benign familial neonatal convulsions. *Neurology* 1993;43:1355–1360.
- Alfonso I, Hahn JS, Papazian O, Martinez YL, Reyes MA, Aicardi J. Bilateral tonic-clonic epileptic seizures in non-benign familial neonatal convulsions. *Pediatr Neurol* 1997;16:249–251.
- Guerra MP, Wilson GA, Boylan GB, Rennie JM. An unusual presentation of fifth-day fits in the newborn. *Pediatr Neurol* 2002;26:398–401.
- Dravet C, Bureau M, Oguni H, Fukuyama Y, Cokar O. Severe myoclonic epilepsy in infancy: Dravet syndrome. *Adv Neurol* 2005;95:71–102.
- Panyiotopoulos CP. Idiopathic epileptic seizures and syndromes in infancy. In: Panyiotopoulos CP, ed. *The epilepsies: seizures, syndromes and management*. Chipping Norton: Bladon Medical Publishing, 2005:117–133.
- Hauser WA. The prevalence and incidence of convulsive disorders in children. *Epilepsia* 1994;35(suppl 2):S1–S6.
- Eriksson KJ, Koivikko MJ. Prevalence, classification, and severity of

epilepsy and epileptic syndromes in children. *Epilepsia* 1997;38:1275–1282.

10. Kramer U, Nevo Y, Neufeld MY, Fatal A, Leitner Y, Harel S. Epidemiology of epilepsy in childhood: a cohort of 440 consecutive patients. *Pediatr Neurol* 1998;18:46–50.
11. Arzimanoglou A, Guerrini R, Aicardi J. Epilepsy in infants. In: Arzimanoglou A, Guerrini R, Aicardi J, eds. *Aicardi's epilepsy in children*. 3rd ed. Philadelphia: Lippincott Williams & Wilkins, 2004:210–219.
12. Fukuyama Y. Borderland of epilepsy with special reference to febrile

convulsions and so-called infantile convulsions. *Seishin-Igaku (Clin Psychiatry)* 1963;5:211–223.

13. Watanabe K, Negoro T, Aso K. Benign partial epilepsy with secondarily generalized seizures in infancy. *Epilepsia* 1993;34:635–638.
14. Caraballo RH, Cersosimo RO, Espeche A, Fejerman N. Benign familial and non-familial infantile seizures: a study of 64 patients. *Epileptic Disord* 2003;5:45–49.
15. Vigeveno F. Benign familial infantile seizures. *Brain Dev* 2005;27:172–177.

NeuroImages

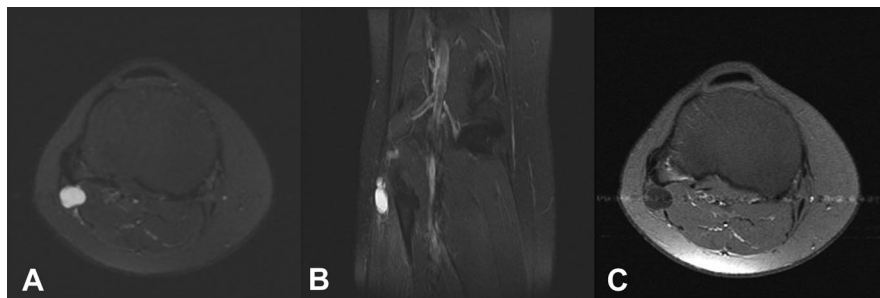


Figure. Right knee MRI: T2 fat saturation images; oblique axial (A) and coronal (B) showing a cystic mass in the lateral right knee. Oblique axial T1 post gadolinium (C) shows no enhancement of the mass.



Peroneal intraneural ganglion

Nandini Bakshi, MD; Krammie M. Chan, MD; and Philip Z. Wirganowicz, MD, Oakland, CA

A 38-year-old woman developed right peroneal mononeuropathy confirmed with electrodiagnostic tests. MRI of the right knee revealed a lobular nonenhancing soft tissue cystic mass extending

along the lateral aspect of the knee just below the fibular head (figure, A through C). Operatively, an intraneural peroneal ganglion was found, which was decompressed, leading to improvement in symptoms.

Peroneal intraneural ganglion cysts are a relatively rare cause of peroneal neuropathy. Imaging studies are helpful in the diagnosis.¹ Although controversy has existed as to the pathogenesis, most are thought to arise from the superior tibiofibular joint.²

Copyright © 2005 by AAN Enterprises, Inc.

Disclosure: The authors report no conflicts of interest.

Address correspondence and reprint requests to Dr. Nandini Bakshi, Department of Neurology, Kaiser Foundation Hospital, 280 West MacArthur Boulevard, Oakland, CA 94611; e-mail: nandini.bakshi@kp.org

1. Lored R, Holder J, Pedowitz R, Yeh LR, Trudell D, Resnick D. MRI of the common peroneal nerve: Normal anatomy and evaluation of masses associated with nerve entrapment. *J Comput Assist Tomogr* 1998;22:925–931.
2. Iverson DJ. MRI detection of cysts of the knee causing common peroneal neuropathy. *Neurology* 2005;65:1829–1831.

See also page 1829

Neurology[®]

Peroneal intraneural ganglion

Nandini Bakshi, Krammie M. Chan and Philip Z. Wirganowicz

Neurology 2005;65;1753

DOI 10.1212/01.wnl.0000186965.04738.ab

This information is current as of December 12, 2005

Updated Information & Services	including high resolution figures, can be found at: http://n.neurology.org/content/65/11/1753.full
References	This article cites 2 articles, 1 of which you can access for free at: http://n.neurology.org/content/65/11/1753.full#ref-list-1
Citations	This article has been cited by 2 HighWire-hosted articles: http://n.neurology.org/content/65/11/1753.full##otherarticles
Subspecialty Collections	This article, along with others on similar topics, appears in the following collection(s): Amyotrophic lateral sclerosis http://n.neurology.org/cgi/collection/amyotrophic_lateral_sclerosis_MRI MRI http://n.neurology.org/cgi/collection/mri
Permissions & Licensing	Information about reproducing this article in parts (figures, tables) or in its entirety can be found online at: http://www.neurology.org/about/about_the_journal#permissions
Reprints	Information about ordering reprints can be found online: http://n.neurology.org/subscribers/advertise

Neurology® is the official journal of the American Academy of Neurology. Published continuously since 1951, it is now a weekly with 48 issues per year. Copyright . All rights reserved. Print ISSN: 0028-3878. Online ISSN: 1526-632X.

