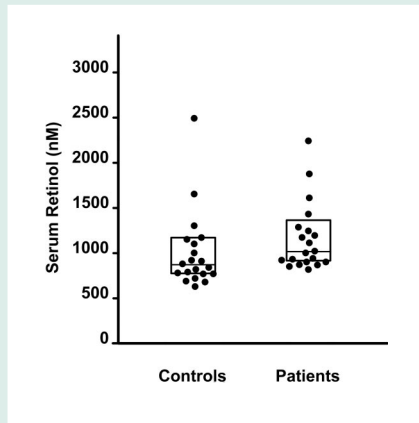


## Vitamin A levels in idiopathic intracranial hypertension



Tabassi et al. assessed serum and CSF retinol levels in 20 patients with idiopathic intracranial hypertension (IIH) and 20 control subjects. They found that elevated CSF but not serum retinol concentration was associated with IIH.

see page 1893

## Is vitamin A implicated in the pathophysiology of increased intracranial pressure?

Commentary by Kathleen Digre, MD, and Judith Warner, MD

Idiopathic intracranial hypertension is a disorder seen in obese women and is characterized by papilledema and increased intracranial pressure, without evidence of venous thrombosis, and in whom no obvious cause can be found. While the disorder has been recognized for more than 100 years, little headway has been made in determining the pathophysiology of the condition. Polar explorers knew that intracranial hypertension could be acquired by eating vitamin A-rich livers of polar bears. Vitamin A-containing medications such as retinoids (e.g., vitamin A, isotretinoin and cis-retinoic acid for acne, trans-retinoic acid for leukemia treatment)<sup>1</sup> have been implicated in the pathophysiology of the condition.

Previous studies about retinoids have shown that serum retinol is increased in some IIH patients vs diet-controlled, aged-matched controls.<sup>2</sup> Increased retinol levels have been found in CSF of some patients with IIH.<sup>3</sup> Selhorst et al. have shown that retinol binding protein (the transport molecule) but not retinol is increased in some with IIH.<sup>4</sup> The Tabassi et al. paper confirms that

retinol is indeed elevated in the CSF of some patients with IIH, and while serum retinol is not significantly increased in IIH, the levels do correlate with CSF levels.

What do these data tell us? First, studying retinol in patients with increased intracranial pressure may be a fruitful avenue of research to understand a possible association or cause of increased intracranial pressure. Second, while there are increased retinol levels in some patients with IIH, not all patients show this association. This would suggest that there are many etiologies for increased intracranial pressure, and retinol may be only one of them. Third we don't know how the increased retinol levels affect the CNS. While it is often speculated that retinol affects absorption of CSF in some way via the arachnoid villus, this is far from proven.

Further research about retinoids should include larger numbers of patients with carefully performed measurements of retinol, retinol binding protein, and transthyretin (a transport molecule in the CNS), and possibly other retinoids (cis-

and trans-retinoic acid) in both the serum and the CSF in patients with IIH, other causes of increased intracranial pressure, neurologic disease states, and normal (age, sex, weight-matched) controls to understand exactly what is normal, what is abnormal, and what role retinol plays in the CNS. Vitamin A appears to be at least a participant in the pathophysiology of IIH, but its exact role is to be determined. Studies are needed to clarify the relationship.

### References

1. Digre KB, Corbett JJ. Idiopathic intracranial hypertension (pseudotumor cerebri): a reappraisal. *The Neurologist* 2001;7:2-67.
2. Jacobson DM, Wall IM, Digre KB, Corbett J. Serum vitamin A concentration is elevated in idiopathic intracranial hypertension. *Neurology* 1999;53:1114-1118.
3. Warner JEA, Bernstein PS, Yemelyanov A, Alder SC, Farnsworth ST, Digre KB. Vitamin A in the cerebrospinal fluid of patients with and without idiopathic intracranial hypertension. *Ann Neurol* 2002;52:647-650.
4. Selhorst J, Kulkantrakorn K, Corbett JJ, Leira EC, Chung SM. Retinol-binding protein in idiopathic intracranial hypertension (IIH). *J Neuroophthalmol* 2000;20:250-252

see page 1893

# Neurology<sup>®</sup>

## **June 14 Highlight and Commentary: Is vitamin A implicated in the pathophysiology of increased intracranial pressure?**

*Neurology* 2005;64;1827  
DOI 10.1212/WNL.64.11.1827

**This information is current as of June 13, 2005**

<b>Updated Information &amp; Services</b>	including high resolution figures, can be found at: <a href="http://n.neurology.org/content/64/11/1827.full">http://n.neurology.org/content/64/11/1827.full</a>
<b>References</b>	This article cites 3 articles, 1 of which you can access for free at: <a href="http://n.neurology.org/content/64/11/1827.full#ref-list-1">http://n.neurology.org/content/64/11/1827.full#ref-list-1</a>
<b>Permissions &amp; Licensing</b>	Information about reproducing this article in parts (figures, tables) or in its entirety can be found online at: <a href="http://www.neurology.org/about/about_the_journal#permissions">http://www.neurology.org/about/about_the_journal#permissions</a>
<b>Reprints</b>	Information about ordering reprints can be found online: <a href="http://n.neurology.org/subscribers/advertise">http://n.neurology.org/subscribers/advertise</a>

*Neurology*® is the official journal of the American Academy of Neurology. Published continuously since 1951, it is now a weekly with 48 issues per year. Copyright . All rights reserved. Print ISSN: 0028-3878. Online ISSN: 1526-632X.

