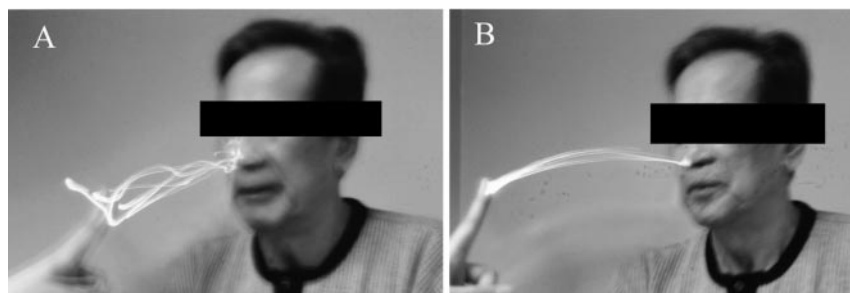


Paroxysmal dysarthria and ataxia after midbrain infarction



Finger-nose test with penlight attached to tip of a finger, during an attack (A) and between attacks (B).

Matsui et al. report a patient with attacks of paroxysmal dysarthria and ataxia after midbrain infarction. SPECT showed hypoperfusion in the parietal lobe contralateral to hemiataxia during the period of paroxysmal attacks.

see page 345

Acquired episodic ataxia and dysarthria

Commentary by Joanna C. Jen, MD, PhD

The participation of the cerebellum in various feedback circuits involving sensorimotor pathways ensures smooth and precise voluntary and involuntary movement. The superior cerebellar peduncle carries efferent cerebellar projections to the red nucleus and thalamus, as well as the reticular formation. Ascending fibers project to the cortex, from which corticopontine fibers originate to descend to the pontine nuclei, with postsynaptic pontocerebellar fibers carried by the middle cerebellar peduncle, thus closing an important feedback loop between the cerebellum and the cortex. Another feedback loop consists of projections from the red nucleus to the inferior olive, which projects to the cerebellum, which in turn projects back to the red nucleus, thereby indirectly modulating descending rubrospinal and reticulospinal tracts. It is well known that disruption at different levels of these circuits can lead to ataxia. Demyelinating lesions in multiple sclerosis can cause paroxysmal ataxia (presumably from ephaptic transmission of demyelinated axons), yet reports of ischemic subcortical lesions causing episodic ataxia have been rare.

The report from Matsui et al. describes a patient with a left midbrain infarct who, 6 weeks later, developed paroxysmal right arm ataxia and dysarthria with increasing frequency. The authors observed left parietal hypoperfusion by SPECT, which the authors correlated with frequent spells

and that improved (but did not normalize) when the patient became free of symptoms after taking phenytoin. The authors hypothesized that sprouting and ephaptic transmission underlies paroxysmal ataxia in this case.

The case study raises interesting hypotheses of CNS injury and repair, but the exact mechanisms require further elucidation and confirmation. Many questions remain unanswered. Did sprouting recur? If so, where did it occur? What triggers paroxysmal ataxia and why should it respond to phenytoin? Diaschisis in the setting of subcortical infarcts is often asymptomatic, and whether parietal hypometabolism accounts for paroxysmal ataxia is speculative; the technique does not allow for temporal resolution for the brief spells in this patient. Phenytoin, which blocks voltage-gated sodium channels, is not known to inhibit sprouting. Whether there may be a reorganization of ion channels zone of ischemic injury to account for altered cell excitability and response to phenytoin brings to mind potentially overlapping mechanisms with congenital episodic ataxia and multiple sclerosis. Two subtypes of episodic ataxia, EA1 and EA2, have been shown to result from defects in ion channels abundantly expressed in the cerebellum. There have been anecdotal reports of responsiveness to anti-epileptics in EA1-associated epilepsy caused by heterozygous mutations in a neuronal voltage-gated potassium channel.

The brief and recurrent nature of the patient's symptoms in this report is more similar to EA1 than EA2. EA1 symptoms are generally not responsive to medications. EA2 can be dramatically responsive to acetazolamide,¹ and a recent report described three EA2 patients who responded to 4-aminopyridine (4-AP), a blocker of potassium channel.² Of note, acetazolamide has been reported to be effective in treating paroxysmal symptoms in multiple sclerosis³ presumed to arise from ephaptic transmission of partially demyelinated axons.⁴ Since demyelination affects the distribution of potassium channels, it may be interesting to look into how MS patients with paroxysmal symptoms may respond 4-AP.

References

1. Griggs RC, Moxley RT 3rd, LaFrance RA, McQuillen J. Hereditary paroxysmal ataxia: response to acetazolamide. *Neurology* 1978;28:1259–1264.
2. Strupp M, Kalla R, Dichgans M, Freilinger T, Glasauer S, Brandt T. Treatment of episodic ataxia type 2 with the potassium channel blocker 4-aminopyridine. *Neurology* 2004;62:1623–1625.
3. Voiculescu V, Pruskauer-Apostol B, Alecu C. Treatment with acetazolamide of brain-stem and spinal paroxysmal disturbances in multiple sclerosis. *J Neurol Neurosurg Psychiatry* 1975;38:191–193.
4. Ostermann PO, Westerberg CE. paroxysmal attacks in multiple sclerosis. *Brain* 1975;98:189–202.

Neurology[®]

July 27 Highlight and Commentary
Neurology 2004;63;197
DOI 10.1212/01.WNL.0000136214.76379.44

This information is current as of July 26, 2004

Updated Information & Services	including high resolution figures, can be found at: http://n.neurology.org/content/63/2/197.full
References	This article cites 4 articles, 3 of which you can access for free at: http://n.neurology.org/content/63/2/197.full#ref-list-1
Permissions & Licensing	Information about reproducing this article in parts (figures, tables) or in its entirety can be found online at: http://www.neurology.org/about/about_the_journal#permissions
Reprints	Information about ordering reprints can be found online: http://n.neurology.org/subscribers/advertise

Neurology® is the official journal of the American Academy of Neurology. Published continuously since 1951, it is now a weekly with 48 issues per year. Copyright . All rights reserved. Print ISSN: 0028-3878. Online ISSN: 1526-632X.

