

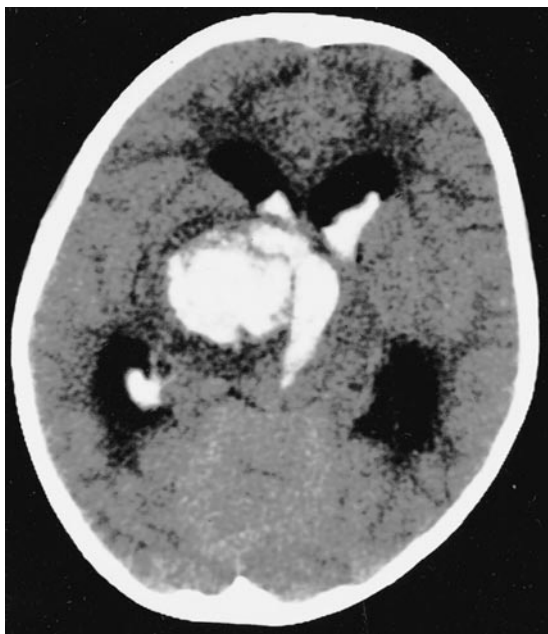Figure 1. CT scan of the brain shows intracerebral hemorrhage over right thalamic area with ventricular extension and hydrocephalus.

### Wyburn-Mason syndrome

Wai-Man Chan, MRCP, FRCS, Nelson K.F. Yip, FRCS,  
Dennis S.C. Lam, FRCS, FRCOphth, Kowloon, Hong Kong

A 9-year-old girl presented with sudden loss of consciousness and CT scan of the brain showed right thalamic hemorrhage with ventricular extension (figure 1). Carotid and vertebral angio-

Address correspondence and reprint requests to Dr. Wai-Man Chan, Associate Professor, Department of Ophthalmology & Visual Sciences, The Chinese University of Hong Kong, Hong Kong Eye Hospital, 147K Argyle Street, Kowloon, Hong Kong; e-mail: cwm6373@netvigator.com

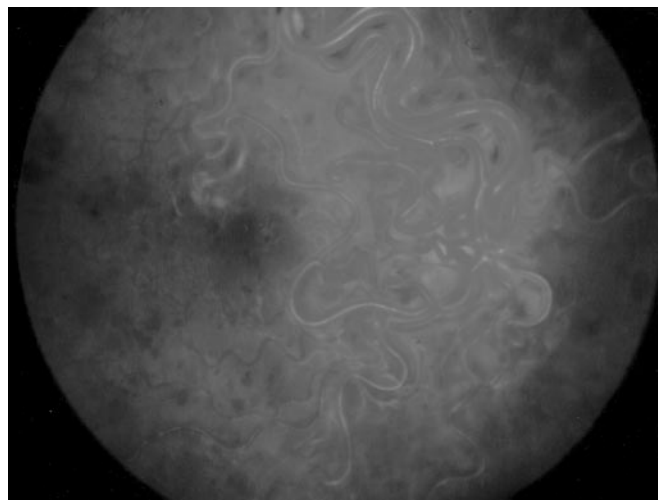


Figure 2. Ophthalmoscopy demonstrates extensive arteriovenous anastomoses involving the entire retina of the right eye. The anomalous vessels are extremely tortuous and congested. The venous stasis caused scattered retinal hemorrhage. The visual acuity of this eye was 20/70.

graphic study revealed a right thalamic arteriovenous malformation (AVM) extending into the right orbit. Ophthalmoscopy demonstrated extensive AVM involving the retina of the right eye (figure 2). A similar eye examination performed 1 year ago had revealed congenital retinal vascular anomalies, but no further investigation was arranged. Unilateral AVM involving the retina, brain, and sometimes skin constitutes Wyburn-Mason syndrome.<sup>1,2</sup> Retinal AVM may signify concomitant intracranial AVM, which warrants detailed neurologic assessment.

1. Patel U, Gupta SC. Wyburn-Mason syndrome. A case report and review of the literature. *Neuroradiology* 1990;31:544-546.
2. Ponce FA, Han PP, Spetzler RF, Canady A, Feiz-Erfan I. Associated arteriovenous malformation of the orbit and brain: a case of Wyburn-Mason syndrome without retinal involvement. Case report. *J Neurosurg* 2001;95:346-349.

# Neurology<sup>®</sup>

## Wyburn-Mason syndrome

Wai-Man Chan, Nelson K.F. Yip and Dennis S.C. Lam

*Neurology* 2004;62;99

DOI 10.1212/01.WNL.0000099187.15025.97

**This information is current as of January 12, 2004**

**Updated Information & Services**

including high resolution figures, can be found at:  
<http://n.neurology.org/content/62/1/99.full>

**References**

This article cites 2 articles, 0 of which you can access for free at:  
<http://n.neurology.org/content/62/1/99.full#ref-list-1>

**Permissions & Licensing**

Information about reproducing this article in parts (figures, tables) or in its entirety can be found online at:  
[http://www.neurology.org/about/about\\_the\\_journal#permissions](http://www.neurology.org/about/about_the_journal#permissions)

**Reprints**

Information about ordering reprints can be found online:  
<http://n.neurology.org/subscribers/advertise>

*Neurology*® is the official journal of the American Academy of Neurology. Published continuously since 1951, it is now a weekly with 48 issues per year. Copyright . All rights reserved. Print ISSN: 0028-3878. Online ISSN: 1526-632X.

