

ity, including discharges that could not be detected at the scalp.<sup>3,4</sup> We believe it is important to consider the possibility that prolonged “postictal” deficits may be due to ongoing ictal discharges, as additional anticonvulsant medication may be indicated.

There were rare periods in this case when there were subtle pseudoperiodic discharges on the scalp EEG during ongoing ictal activity intracranially, and persistent aphasia. This supports the view that in some instances, periodic lateralized epileptiform discharges (PLED) on the scalp EEG are actually ictal.<sup>5</sup> It is possible that functional imaging with PET or SPECT can help make this differentiation, as focal increased blood flow or metabolism during a prolonged postictal deficit or during PLED may suggest an ictal state.<sup>6</sup> This was not performed in our patient.

We conclude that prolonged “postictal” deficits may sometimes be due to ongoing ictal activity that is not evident on scalp EEG.

*From the Comprehensive Epilepsy Center, Columbia University College of Physicians & Surgeons, New York–Presbyterian Hospital, Columbia Campus, New York.*

*Received March 13, 2000. Accepted in final form August 31, 2000.*

*Address correspondence and reprint requests to Dr. L.J. Hirsch, Comprehensive Epilepsy Center, Columbia University College of Physicians & Surgeons, New York–Presbyterian Hospital, Columbia Campus, 710 West 168th Street, New York, NY 10032; e-mail: LJH3@columbia.edu*

Copyright © 2001 by AAN Enterprises, Inc.

## References

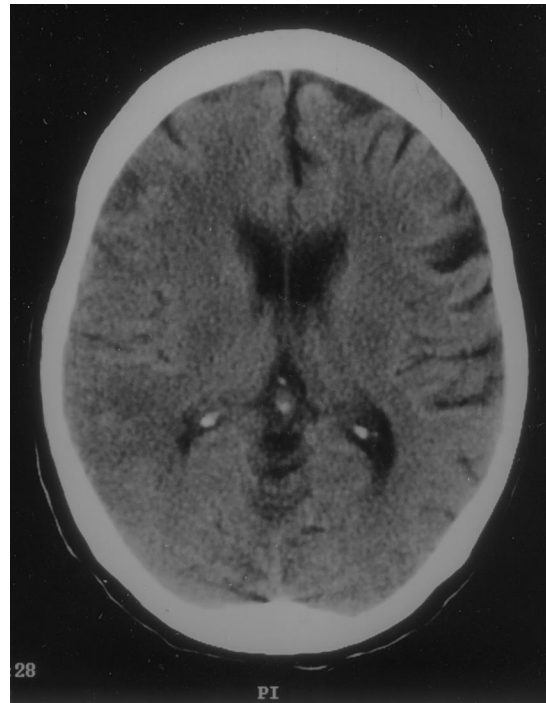1. Primavera A, Bo G-P, Venturi S. Aphasic status epilepticus. *Eur Neurol* 1988;28:255–257.
2. Grimes DA, Guberman A. De novo aphasic status epilepticus. *Epilepsia* 1997;38:945–949.
3. Regard M, Cook ND, Wieser HG, Landis T. The dynamics of cerebral dominance during unilateral limbic seizures. *Brain* 1994;117:91–104.
4. Wieser HG, Hailemariam S, Regard M, Landis T. Unilateral limbic epileptic status activity: stereo EEG, behavioral, and cognitive data. *Epilepsia* 1985;26:19–29.
5. Pohlmann–Eden B, Hoch DB, Cochius JI, Chiappa KH. Periodic lateralized epileptiform discharges—a critical review. *J Clin Neurophysiol* 1996;13:519–530.
6. Handforth A, Cheng JT, Mandelkern MA, Treiman DM. Markedly increased mesiotemporal lobe metabolism in a case with PLEDs: further evidence that PLEDs are a manifestation of partial status epilepticus. *Epilepsia* 1994;35:876–881.

## Cerebral artery air embolism following an esophagogastroscope: A case report

*Naveed Akhtar, MBBS; Wasim Jafri, MBBS, FRCP; and Tahseen Mozaffar, MBBS*

Cerebrovascular events during endoscopy are uncommon. Air embolism should be considered in the differential diagnosis of any stroke, particularly if it develops during or after an endoscopic procedure. We report this unusual complication in a woman who had a cerebral artery air embolism during an esophagogastroscope procedure.

**Case report.** An 80-year-old woman presented with a history of progressive dysphagia, initially for solid foods and later for liquids, and severe weight loss during the previous 6 months. She was taking enalapril for hypertension. Initial investigations revealed the presence of a malignant stricture in the esophagus. She underwent an elective fiberoptic endoscopy under conscious sedation, which confirmed a malignant stricture at the esophagogastric junction, along with a small esophagotracheal fistula. Multiple small biopsies were performed, confirming the presence of esophageal carcinoma. Her level of consciousness deteriorated immediately following the procedure. She became unresponsive, but remained hemodynamically stable. Examination revealed a left hemiparesis involving the face, arm, and leg, with flexion of the right upper limb in response to pain. An emergent unenhanced CT scan of the head revealed parenchymal air in the right hemisphere (figure). Right-sided sulci were effaced, which was suggestive of an acute right middle cerebral artery infarct. Cerebral air embolism was diagnosed. She was treated conservatively with 100% oxygen therapy. A transthoracic echocardiogram with bubble contrast showed no evidence of a right-to-left intracardiac shunt. She was discharged from the hospital in a vegetative state 2 weeks after admission.



*Figure. Unenhanced CT scan of head shows right hemispheric swelling and effacement of gyri on that side. Free parenchymal air is seen in the subfrontal region.*

**Discussion.** Cerebral air embolism may occur with barotrauma<sup>1</sup> and during neurosurgical procedures,<sup>2</sup> especially when performed in a sitting position. This also has been reported as a complication of cardiac catheterization, as well as in other diagnostic and therapeutic procedures.<sup>3</sup> A few cases have been reported in the absence of intracardiac defects. Penetrating duodenal ulcers may form fistulas with colon, pancreatic or bile duct, or aorta. Other cases have been reported with duodenocaval fistulas after trauma and local radiation.<sup>4</sup>

Because of unique hepatic venous drainage, systemic air embolism is uncommon with gastrointestinal endoscopy procedures. Venous air embolism occurs only when the liver is bypassed, e.g., with portosystemic shunts in portal hypertension. Arterial air embolism is even more rare because of capillary filtration in the lungs. In certain circumstances, this filter is bypassed through a right-to-left intracardiac shunt.<sup>5</sup> However, in our patient, such a shunt was not found. A small tracheoesophageal fistula around the stricture was seen. There have been reports of a fatal cerebral arterial gas embolism caused by a large venous gas embolism, though no intracardiac defects or shunt mechanisms could be demonstrated.<sup>3</sup> An alternative mechanism for paradoxical air embolism—intrapulmonary shunts as well as transcapillary route with large air emboli—has been proposed.<sup>6</sup> This probably best explains the mechanism in our patient.

The neurologic manifestations are myriad and include altered consciousness, seizures, and focal deficit. CT scanning is valuable in detecting this if performed early, as IV air is rapidly absorbed and delays would result in a failure of diagnosis. CNS dysfunction results from mechanical obstruction of arterioles, leading to cerebral ischemia and the thrombotic-inflammatory response of air-injured epithelium. This results in a transient decline of cerebral blood flow and neural function. Treatment should be started as soon as there is a strong clinical suspicion for the diagnosis, including the removal of the air source, 100% oxygen by face mask, and hyperbaric oxygen. The aim of this treatment is to rapidly reduce the volume of air embolus. Recent experimental data suggest that agents with antithrombotic and anti-inflammatory properties may be of potential benefit when given prophylactically in subjects at risk for cerebral air embolism.<sup>5,6</sup>

*From the Departments of Medicine—Neurology (Drs. Akhtar and Mozaffar), Gastroenterology (Dr. Jafri), and Pathology (Dr. Mozaffar), the Aga Khan University Medical College, Karachi, Pakistan.*

## References

1. Neumann TS, Hallenbeck JM. Barotraumatic cerebral air embolism and mental status examination. A report of four cases. *Ann Emerg Med* 1987;16:220–223.
2. Tommasino C, Rissardi R, Baretta L. Cerebral ischemia after venous air embolism in absence of intracardiac defects. *J Neurosurg Anesth* 1996;1:30–34.
3. Muth CM, Shank ES. Gas embolism. *N Engl J Med* 2000;342:476–482.
4. Dalsgaard S, Varmerkan JE. Duodenal ulcer and perforation to inferior vena cava. *Acta Chir Scand* 1985;151:181–182.
5. Ryu KH, Hindman BJ, Reasoner DK, Dexter F. Heparin reduces neurologic impairment after cerebral artery air embolism in rabbit. *Stroke* 1996;27:303–309.
6. Reasoner DK, Hindman BJ, Dexter F, Susieta A, Cutkomp J, Smith T. Doxycycline reduces early neurologic impairment after cerebral artery air embolism in the rabbit. *Anesthesiology* 1997;87:569–790.

## Chorea and antiphospholipid antibodies: Treatment with methotrexate

S. Paus, MD; B. Pötzsch, MD; J.H. Risse, MD; T. Klockgether, MD; and U. Willner, MD

Chorea may occur in systemic lupus erythematosus (SLE) and primary antiphospholipid antibody syndrome (PAPS). Vascular lesions and immune-mediated excitatory mechanisms have been proposed as the underlying pathophysiology.<sup>1,2</sup> Accordingly, immunosuppressive therapy has been employed in antiphospholipid antibody (aPL)-associated chorea.<sup>3,5</sup> We report the correlation between clinical symptoms, laboratory activity of aPL, and striatal hypermetabolism in <sup>18</sup>F-fluorodeoxyglucose (FDG) PET in a patient with aPL-associated hemichorea. This patient was successfully treated with low-dose methotrexate.

**Case report.** A 41-year-old right-handed woman developed involuntary movements of the left hand in June 1999. Within 2 weeks, the symptoms progressed to uncontrollable jerks of the left arm and leg, with clumsiness of finger movements, twitching of the left face with squeezing of the eye, and speech difficulties due to clumsiness of the tongue. She was unable to continue working. Her medical history included moderate hypertension treated with losartan 50 mg per day, hysterectomy, and cigarette smoking (12 pack-years). Family history of movement disorders was negative.

A cranial MRI revealed no ischemic lesion. CSF, EEG, intra- and extracranial DCI, and ophthalmologic examination results were normal. Tests for lupus anticoagulant (LA) were positive, with increased activated partial thromboplastin time (aPTT) (38.7 s; normal, 21.0 to 36.0 s) and dilute Russell viper venom time ratio (dRVVT-ratio) (2.2; normal, <1.2); the anticardiolipin antibody titer (IgG) (aCL-IgG) was elevated (86.0 U/mL; normal, <18 U/mL). All other laboratory results including platelet count, complement factor 3 and 4, anti-ds-DNA antibodies, antinuclear antibodies, HIV antibodies, treponema pallidum hemagglutination assay (serum and CSF), acanthocytes, serum copper and ceruloplasmin, and thyroid function were normal. A preliminary diagnosis of aPL-associated chorea was made.

Six weeks after the first manifestation of chorea, treatment was initiated with low-dose methotrexate, 20 mg orally once per week, which led to a rapid improvement. After 4 weeks of continuous medication, choreatic movements were no longer detectable and the laboratory follow-up showed an improved result for aCL-IgG (55.7 U/mL) and a downward trend of LA (aPTT 34.5 s; dRVVT-ratio 1.7).

Methotrexate treatment was discontinued after 9 weeks. Eight days after the last intake, the patient again noticed involuntary

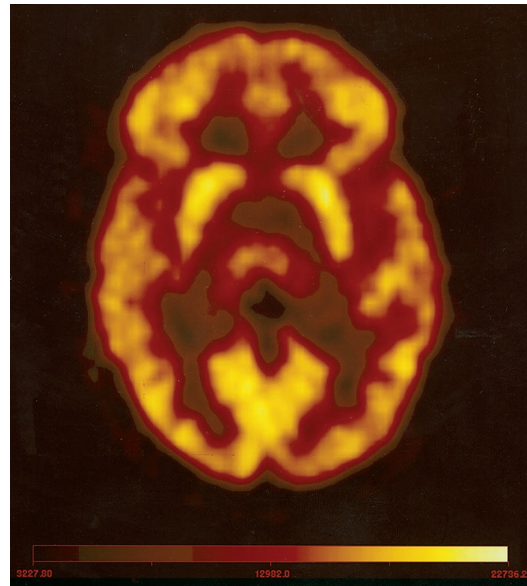


Figure. <sup>18</sup>F-fluorodeoxyglucose (FDG) PET during a relapse after withdrawal of methotrexate. FDG uptake is enhanced in the right caput nuclei caudati (CNC) as compared with the contralateral side. Regions of interest in this plane revealed maximal standard uptake values of 6.3 (right CNC) and 5.8 (left CNC).

movements of the left hand and foot. Neurologic examination 12 days after the last methotrexate intake confirmed a mild to moderate relapse of left-sided hemichorea. Laboratory results showed increased LA (aPTT 39.5 s; dRVVT-ratio 1.9) and aCL-IgG (75.2 U/mL). An FDG PET performed to study striatal hypermetabolism revealed an increase of FDG uptake in the right caudate nucleus as compared with the left side ( $6.36 \pm 1.5\%$ ;  $p < 0.05$ ) (figure).

Medication was started again at 20 mg methotrexate per week. After 2 weeks, choreatic movements were no longer detectable. After 6 weeks of continuous medication, FDG PET revealed no difference between FDG uptake values of the left and right caudate nucleus. The laboratory follow-up showed a downward trend of dRVVT-ratio (1.7) and aCL-IgG (67.3 U/mL), whereas aPTT was nearly unchanged (42.0 s).

**Discussion.** This case of aPL-associated hemichorea documents an association between intensity of choreatic symptoms, laboratory activity of aPL, striatal hypermetabolism, and immunosuppressive therapy with methotrexate. Our results are consistent with earlier suggestions that aPL-associated chorea is caused by an immune-mediated excitatory effect of aPL resulting in striatal hypermetabolism measurable by PET, rather than a consequence of ischemic lesions in the basal ganglia.<sup>5,6</sup>

Chorea associated with aPL in adults has been reported in SLE, lupus-like syndrome, and PAPS.<sup>3</sup> In patients who do not fulfill the criteria of the American College of Rheumatologists for these disorders, as in our case, chorea might be an early symptom of SLE or PAPS, antedating the disease for several years,<sup>3</sup> or the only manifestation of aPL.

A search of the literature revealed high-dose corticosteroids, cyclophosphamide, and combinations of the two as the most frequently used medication in aPL-associated chorea. The dramatic response to oral application of low-dose methotrexate, however, demonstrates that treatment with methotrexate alone may provide a reasonable and effective alternative.

From the Departments of Neurology (Drs. Paus, Klockgether, and Willner) and Nuclear Medicine (Dr. Risse), and the Institute of Experimental Haematology and Transfusion Medicine (Dr. Pötzsch), University of Bonn, Germany.

Received June 1, 2000. Accepted in final form August 24, 2000.

# Neurology<sup>®</sup>

## **Cerebral artery air embolism following an esophagogastroscopy: A case report**

Naveed Akhtar, Wasim Jafri and Tahseen Mozaffar

*Neurology* 2001;56;136-137

DOI 10.1212/WNL.56.1.136

**This information is current as of January 9, 2001**

<b>Updated Information &amp; Services</b>	including high resolution figures, can be found at: <a href="http://n.neurology.org/content/56/1/136.full">http://n.neurology.org/content/56/1/136.full</a>
<b>References</b>	This article cites 5 articles, 1 of which you can access for free at: <a href="http://n.neurology.org/content/56/1/136.full#ref-list-1">http://n.neurology.org/content/56/1/136.full#ref-list-1</a>
<b>Subspecialty Collections</b>	This article, along with others on similar topics, appears in the following collection(s): <b>Embolism</b> <a href="http://n.neurology.org/cgi/collection/embolism">http://n.neurology.org/cgi/collection/embolism</a> <b>Gastrointestinal</b> <a href="http://n.neurology.org/cgi/collection/gastrointestinal">http://n.neurology.org/cgi/collection/gastrointestinal</a>
<b>Permissions &amp; Licensing</b>	Information about reproducing this article in parts (figures, tables) or in its entirety can be found online at: <a href="http://www.neurology.org/about/about_the_journal#permissions">http://www.neurology.org/about/about_the_journal#permissions</a>
<b>Reprints</b>	Information about ordering reprints can be found online: <a href="http://n.neurology.org/subscribers/advertise">http://n.neurology.org/subscribers/advertise</a>

*Neurology*® is the official journal of the American Academy of Neurology. Published continuously since 1951, it is now a weekly with 48 issues per year. Copyright . All rights reserved. Print ISSN: 0028-3878. Online ISSN: 1526-632X.

