

# Teaching NeuroImage: Intraventricular Fetus-in-Fetu With Extensive De Novo Gain in Genetic Copy Number

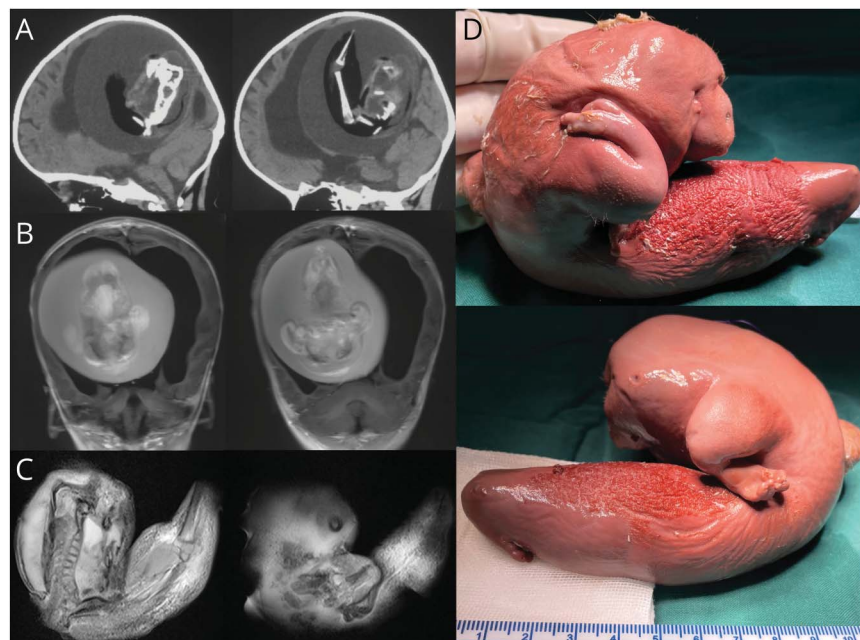
Zongze Li, MD, Li Ma, MD, PhD, Yuanli Zhao, MD, PhD, and Chunde Li, MD

*Neurology*® 2023;100:444-445. doi:10.1212/WNL.0000000000201578

**Correspondence**

Dr. Li  
lichunde@bjtth.org

**Figure 1** Imaging of Fetus-in-Fetu



Head CT (A) and T1-weighted image (B) of an infant showing hydrocephalus, compressed brain, and intraventricular mass with vertebral column, femur, and tibia. T1-weighted image of the mass revealing spinal bifida (C). The fetiform mass with upper limb and finger-like buds (D).

An intraventricular fetus-in-fetu, a malformed monozygotic diamniotic twin, was identified in a 1-year-old girl with motor delay and enlarged head circumference (Figure 1). After surgical removal, whole-genome sequencing revealed identical single-nucleotide variants in the host child and fetus-in-fetu, with extensive de novo copy number gains in the fetus-in-fetu (Figure 2, eMethods, [links.lww.com/WNL/C529](https://links.lww.com/WNL/C529)), suggesting the significance of copy number variation during embryogenesis.

The intracranial fetus-in-fetu is proposed to arise from unseparated blastocysts. The conjoined parts develop into the forebrain of host fetus and envelop the other embryo during neural plate folding.<sup>1</sup> Fetus-in-fetu can be distinguished from teratomas based on the younger age of presenting patients and the presence of vertebrae or internal organs.<sup>2</sup>

## MORE ONLINE

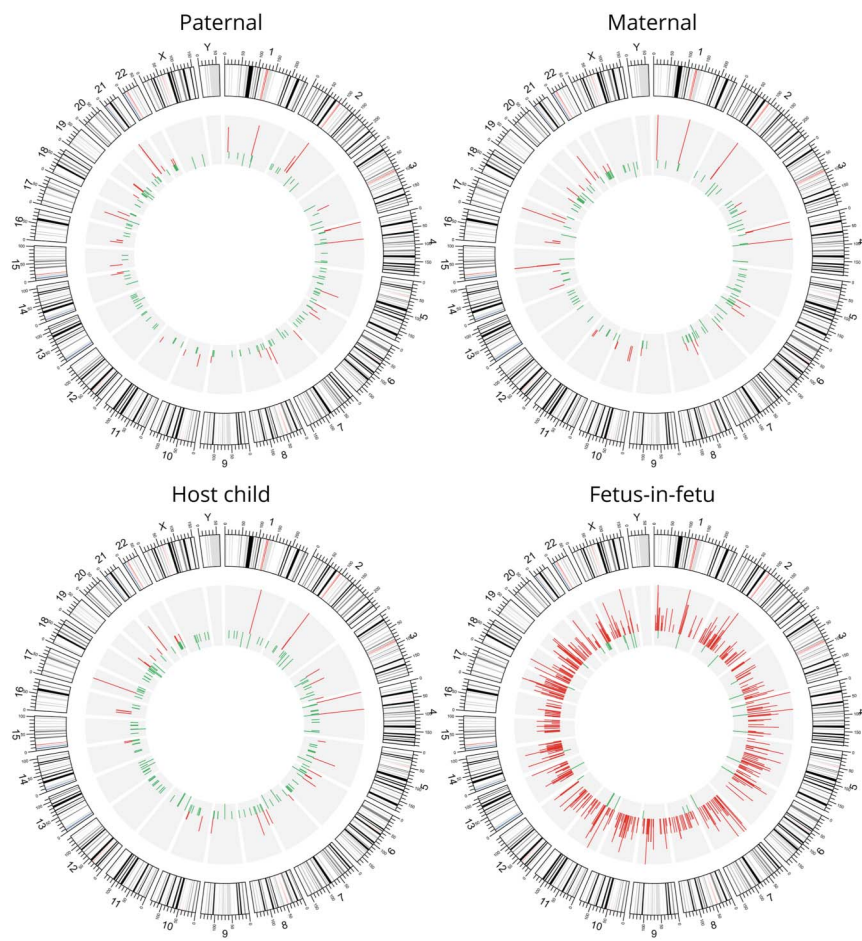
### Teaching Slides

[links.lww.com/WNL/C530](https://links.lww.com/WNL/C530)

From the Department of Neurosurgery (Z.L.), Huashan Hospital, Fudan University, Shanghai, P.R.China; Department of Neurosurgery (L.M., Y.Z., C.L.), Beijing Tiantan Hospital, Capital Medical University, P.R.China; and Department of Neurosurgery (Y.Z.), Peking University International Hospital, Beijing, P.R.China.

Go to [Neurology.org/N](https://Neurology.org/N) for full disclosures. Funding information and disclosures deemed relevant by the authors, if any, are provided at the end of the article.

**Figure 2** Copy Number Duplication in Fetus-in-Fetu



Red bands indicating copy number gain.

### Author Contributions

Z. Li: drafting/revision of the manuscript for content, including medical writing for content. L. Ma: study concept or design; analysis or interpretation of data. Y. Zhao: major role in the acquisition of data; study concept or design. C. Li: major role in the acquisition of data; Study concept or design.

### Study Funding

This project was supported by the National Natural Science Foundation of China (81801140 to Dr Ma and 81571110, 81771234 to Dr Zhao).

### Disclosure

The authors report no relevant disclosures. Go to [Neurology.org/N](https://www.neurology.org/N) for full disclosures.

### Publication History

Received by *Neurology* June 17, 2022. Accepted in final form October 6, 2022. Submitted and externally peer reviewed. The handling editor was Resident and Fellow Section Editor Whitley Aamodt, MD, MPH.

### References

1. Miura S, Miura K, Yamamoto T, et al. Origin and mechanisms of formation of fetus-in-fetu: two cases with genotype and methylation analyses. *Am J Med Genet A*. 2006;140A(16), 1737-1743.
2. Huddle LN, Fuller C, Powell T, et al. Intraventricular twin fetuses in fetu. *J Neurosurg Pediatr*. 2012;9(1), 17-23.

# Neurology®

## Teaching NeuroImage: Intraventricular Fetus-in-Fetu With Extensive De Novo Gain in Genetic Copy Number

Zongze Li, Li Ma, Yuanli Zhao, et al.

*Neurology* 2023;100;444-445 Published Online before print December 12, 2022

DOI 10.1212/WNL.0000000000201578

**This information is current as of December 12, 2022**

<b>Updated Information &amp; Services</b>	including high resolution figures, can be found at: <a href="http://n.neurology.org/content/100/9/444.full">http://n.neurology.org/content/100/9/444.full</a>
<b>References</b>	This article cites 2 articles, 0 of which you can access for free at: <a href="http://n.neurology.org/content/100/9/444.full#ref-list-1">http://n.neurology.org/content/100/9/444.full#ref-list-1</a>
<b>Subspecialty Collections</b>	This article, along with others on similar topics, appears in the following collection(s): <b>All Genetics</b> <a href="http://n.neurology.org/cgi/collection/all_genetics">http://n.neurology.org/cgi/collection/all_genetics</a> <b>All Pediatric</b> <a href="http://n.neurology.org/cgi/collection/all_pediatric">http://n.neurology.org/cgi/collection/all_pediatric</a>
<b>Permissions &amp; Licensing</b>	Information about reproducing this article in parts (figures, tables) or in its entirety can be found online at: <a href="http://www.neurology.org/about/about_the_journal#permissions">http://www.neurology.org/about/about_the_journal#permissions</a>
<b>Reprints</b>	Information about ordering reprints can be found online: <a href="http://n.neurology.org/subscribers/advertise">http://n.neurology.org/subscribers/advertise</a>

*Neurology*® is the official journal of the American Academy of Neurology. Published continuously since 1951, it is now a weekly with 48 issues per year. Copyright © 2022 American Academy of Neurology. All rights reserved. Print ISSN: 0028-3878. Online ISSN: 1526-632X.

