

# Teaching NeuroImages: Nonfluent variant primary progressive aphasia

## A distinctive clinico-anatomical syndrome

**OPEN**

Charles R. Marshall,  
MRCP  
Christopher J.D. Hardy,  
MSc  
Martin N. Rossor, MD  
Jason D. Warren, PhD

Correspondence to  
Dr. Marshall:  
charles.marshall@ucl.ac.uk

A 66-year-old woman presented with 4 years of progressive speech difficulty. She had nonfluent speech with phonemic errors but intact single-word comprehension and object knowledge. Her grammar was impaired in both speech and writing, and she exhibited orofacial apraxia. A clinico-radiologic (see figure) diagnosis of nonfluent variant primary progressive aphasia was made.

Nonfluent variant primary progressive aphasia is a neurodegenerative disease within the spectrum of frontotemporal dementia, characterized by the typical language and brain atrophy patterns seen here.<sup>1</sup> It is most frequently due to tau pathology, and clinicians should be alert to the potential development of progressive supranuclear palsy or corticobasal syndrome.<sup>2</sup>

### AUTHOR CONTRIBUTIONS

C.R.M.: image selection and drafting of the manuscript. C.J.D.H., M.N.R., J.D.W.: critical revisions of the manuscript.

### STUDY FUNDING

The Dementia Research Centre is grateful for the support of the NIHR Queen Square Dementia Biomedical Research Unit. The Article Processing Charge was paid by Wellcome Trust.

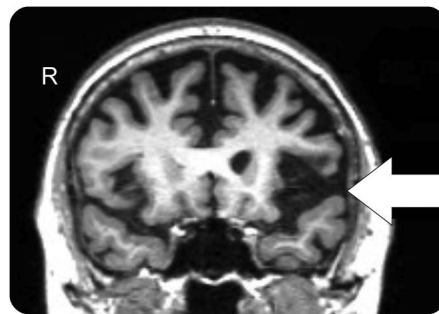
### DISCLOSURE

C. Marshall is funded by a clinical fellowship from the Leonard Wolfson Experimental Neurology Centre at UCL. C. Hardy holds an MRC PhD studentship. M. Rossor is an NIHR investigator. J. Warren is a Wellcome Trust Senior Fellow. Go to [Neurology.org](http://Neurology.org) for full disclosures.

### REFERENCES

1. Gorno-Tempini ML, Hillis AE, Weintraub S, et al. Classification of primary progressive aphasia and its variants. *Neurology* 2011;76:1006–1014.
2. Josephs KA, Duffy JR. Apraxia of speech and nonfluent aphasia: a new clinical marker for corticobasal degeneration and progressive supranuclear palsy. *Curr Opin Neurol* 2008;21:688–692.

**Figure** Magnetic resonance image



Coronal volumetric T1-weighted MRI showing asymmetric atrophy of left insula and opercular inferior frontal gyrus (arrow), a pattern typical of nonfluent variant primary progressive aphasia.

Download teaching slides:  
[Neurology.org](http://Neurology.org)

From the Dementia Research Centre, University College London, UK.

This is an open access article distributed under the terms of the Creative Commons Attribution Licence 4.0 (CC BY), which permits unrestricted use, distribution, and reproduction in any medium, provided the original work is properly cited.

Republished from *Neurology* 2011;87(23):e283. doi: 10.1212/WNL.00000000000003408

© 2016 American Academy of Neurology

# Neurology<sup>®</sup>

## Teaching *NeuroImages*: Nonfluent variant primary progressive aphasia: A distinctive clinico-anatomical syndrome

Charles R. Marshall, Christopher J.D. Hardy, Martin N. Rossor, et al.

*Neurology* 2023;100;S27

DOI 10.1212/WNL.0000000000206915

This information is current as of April 21, 2023

<b>Updated Information &amp; Services</b>	including high resolution figures, can be found at: <a href="http://n.neurology.org/content/100/16_Supplement_1/S27.full">http://n.neurology.org/content/100/16_Supplement_1/S27.full</a>
<b>References</b>	This article cites 2 articles, 1 of which you can access for free at: <a href="http://n.neurology.org/content/100/16_Supplement_1/S27.full#ref-list-1">http://n.neurology.org/content/100/16_Supplement_1/S27.full#ref-list-1</a>
<b>Subspecialty Collections</b>	This article, along with others on similar topics, appears in the following collection(s): <b>All Cognitive Disorders/Dementia</b> <a href="http://n.neurology.org/cgi/collection/all_cognitive_disorders_dementia">http://n.neurology.org/cgi/collection/all_cognitive_disorders_dementia</a> <b>Aphasia</b> <a href="http://n.neurology.org/cgi/collection/aphasia">http://n.neurology.org/cgi/collection/aphasia</a> <b>Apraxia</b> <a href="http://n.neurology.org/cgi/collection/apraxia">http://n.neurology.org/cgi/collection/apraxia</a> <b>Frontotemporal dementia</b> <a href="http://n.neurology.org/cgi/collection/frontotemporal_dementia">http://n.neurology.org/cgi/collection/frontotemporal_dementia</a> <b>Volumetric MRI</b> <a href="http://n.neurology.org/cgi/collection/volumetric_mri">http://n.neurology.org/cgi/collection/volumetric_mri</a>
<b>Permissions &amp; Licensing</b>	Information about reproducing this article in parts (figures, tables) or in its entirety can be found online at: <a href="http://www.neurology.org/about/about_the_journal#permissions">http://www.neurology.org/about/about_the_journal#permissions</a>
<b>Reprints</b>	Information about ordering reprints can be found online: <a href="http://n.neurology.org/subscribers/advertise">http://n.neurology.org/subscribers/advertise</a>

*Neurology*® is the official journal of the American Academy of Neurology. Published continuously since 1951, it is now a weekly with 48 issues per year. Copyright © 2016 American Academy of Neurology. All rights reserved. Print ISSN: 0028-3878. Online ISSN: 1526-632X.

